



Case Report

First Report of *Taenia taeniaeformis* in Persian Leopard (*Panthera pardus saxicolor*) in Iran

B. Esfandiari and M. R. Youssefi^{1*}

Pasteur Institute of Iran-Amol Research Center, Amol, Mazandaran, Iran; ¹Department of Veterinary Parasitology, Islamic Azad University, Babol-Branch, Babol, Iran

*Corresponding author: youssefi929@hotmail.com

ARTICLE HISTORY

Received: March 20, 2010

Revised: June 21, 2010

Accepted: July 04, 2010

Key words:

Iran

Persian leopard

Taenia taeniaeformis

ABSTRACT

Taenia taeniaeformis is synonym of *Taenia infantis*, *Hydatigera taeniaeformis* and *Multiceps longihamatus*. It has worldwide distribution. The leopard, a young female 2-3 years and body weight of 35 Kg, was shot unwillingly in a frighteningly close encounter with villagers in Ahovan County, Damghan city, Iran. One cestode obtained was identified as *Taenia taeniaeformis*. The worm was white, thick bodied and about 15 cm in length. The rostellum was short and armed with a double row of 28 hooks of two sizes.

©2010 PVJ. All rights reserved

To cite this article: B. Esfandiari and M. R. Youssefi, 2010. First report of *Taenia taeniaeformis* in Persian leopard (*Panthera pardus saxicolor*) in Iran. Pak Vet J, 30(x): xxx.

INTRODUCTION

Taenia taeniaeformis is synonym to *Taenia infantis* (Bacigalupo, 1922), *Hydatigera taeniaeformis* (Batsch, 1786), *Multiceps longihamatus* (Morishita and Sawada, 1966; Bowman *et al.*, 2002). This worm has been known for some time both as adult found in the cat and in the segmented larval stage in the liver of rodents, the strobilocercus. The larval stage was first described as *Cysticercus fasciolaris* by Rudolphi (Rudolphi, 1808). *Taenia taeniaeformis* has worldwide distribution, it parallels that of the domestic cat. The adult tapeworms tend to be located such that the scolex is within the first one-half of the small intestine. The scolex is often found attached to the mucosa (Alcaino *et al.*, 1992).

Taenia taeniaeformis is the most robust of the tapeworm parasites found in the cat (Nolan and Smith, 1995). This is also the only species of *Taenia* typically reported from the domestic cat around the world. The worm tends to be white, thick bodied and about 15 to 60 cm in length. The scolex has two rows of hooks that have the typical claw-hammer shape of the Taeniidae. There tends to be somewhere between 30 to 50 hooks per scolex. Each of the mature segments possesses a single lateral genital opening that randomly occurs on either one lateral side of a segment or the other (Okamoto *et al.*, 1995). Present paper describes the detection of *Taenia taeniaeformis* in a leopard (*Panthera pardus saxicolor*) in Iran, which is the first report of this parasite in Iran.

History

The Persian leopard is said to be one of the largest of all the subspecies of leopards in the world. The leopard is the smallest of the great cats (lion, tiger, and jaguar). Males are up to 50% larger than the females. They are killed by farmers because they pose a threat to their livestock.

The leopard, a young female 2-3 years age, head and trunk length 120 cm, length of tail 98cm and body weight of 35 Kg, was shot unwillingly in a frighteningly close encounter with villagers in Ahovan County around Damghan city (Latitude 36.083°, longitude 58.967° and elevation 1238', East Semnan province). Three days after the leopard was killed, the carcass was freezeed and transferred to the Department of Veterinary Parasitology, Tehran University of Medical Sciences, Tehran. Then, digestive tract was examined for endoparasites with screen (Mesh 70). The specimens were fixed and preserved in a solution containing 70 % ethanol and 10% formalin. Then these specimens were studied in wet and temporary mounts.

PROCEDURE AND RESULTS

For definitive identification, preliminary samples were dispatched to Veterinary Parasitology Museum, University of Tehran. Worm staining was done by carmine acid procedures. Dissected rostellum was mounted in aceto carmine. The number, shape, arrangement of rostellar hook and morphological characteristics of the mature segment were studied. Based

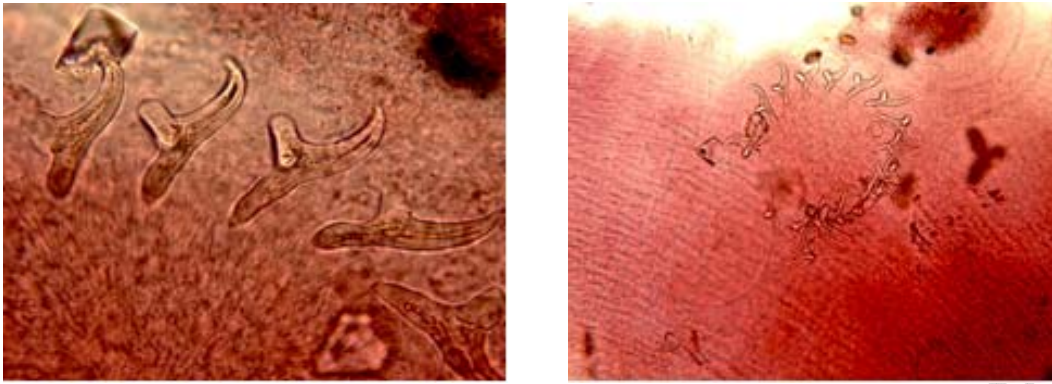


Fig. 1: Rostellum (left) and hook (right) *Taenia taeniaeformis* detected of (*Panthera pardus saxicolor*) in Iran.

on the morphology characteristics (Yamaguti, 1963), one cestode helminth obtained was identified as *Taenia taeniaeformis*. The worm was white, thick bodied and about 15 cm in length. The rostellum was short and armed with a double row of 28 hooks of two sizes (Fig. 1). The larger hooks are measured to be 169 μm and the smaller ones to be 125 μm . Each of the mature segments possesses a single lateral genital opening that randomly occurs on either lateral side of a segment or the other. The terminal, gravid segments present in the feces were packed with eggs. The gravid uterus had 8 branches on each side. Under microscope, *Taenia* eggs revealed typical brown-shelled taeniid eggs containing six-hooked larvae. The eggs of *Taenia taeniaeformis* were spherical and measured between 31 to 36 μm in diameter.

DISCUSSION

Many species of *Taenia* are found in carnivores; Verster (1969) recognized 29 valid species and several of questionable validity. Some species are found in large cats as the final host including, *Taenia gonyamiae*, *Taenia ingwei*, *Taenia omissa* and *Taenia macrocystis*. Other final hosts could be hyaenas, mustellids, foxes, and viverids. This is the first report from Iran that *Taenia taeniaeformis* found in Persian leopard. *Taenia taeniaeformis* is found worldwide where suitable hosts are present. It is not specific to any particular region. *Taenia taeniaeformis* infects rodents and felines so it is mainly a terrestrial organism. In unusual circumstances it has been found in humans, but very rare. It infects leopard mainly by way of mice. The infected mouse (secondary intermediate host) when eaten by the feline, the worm could develop to its adult stage in the intestine of the feline (Yamaguti, 1963). Identification of the species is based on the size and shape of the hooks on the rostellum

along with various other characters, such as the type of larval stage, position of the genital ducts relative to the longitudinal excretory canals, etc., as has been carried out in this case report.

REFERENCES

- Alcaino H, T Gorman and I Larenas, 1992. Endoparasitological fauna of the domestic cat in an urban zone of the metropolitan region, Chile. *Parasitologia al Dia*, 16: 139-142.
- Bacigalupo J, 1922. Sobre una nueva especie de *Taenia*, *Taenia infantis*. *Semana Med*, 26: 726-729.
- Bowman D, MC Hendrix, DS Lindsay and SC Barr, 2002. *Feline Clinical Parasitology*. 1st Ed., Iowa State University Press, A Blackwell Science Company, Iowa, USA. pp: 219-225.
- Morishita K and I Sawada, 1966. On tapeworms of the genus *Multiceps* hitherto unrecorded from man. *Jap J Parasitol*, 15: 495-501.
- Nolan TJ and G Smith, 1995. Time series analysis of the prevalence of endoparasitic infections in cats and dogs presented to a veterinary teaching hospital. *Vet Parasitol*, 59: 87-96.
- Okamoto M, Y Bessho, M Kamiya, T Kurosawa and T Horii, 1995. Phylogenetic relationships within *Taenia taeniaeformis* variants and other taeniid cestodes inferred from the nucleotide sequence of the cytochrome c oxidase subunit I gene. *Parasitol Res*, 81: 451-458.
- Yamaguti S, 1963. *Systema helminthum*. Vol.3. Interscience Publishers, A Division of John Wiley & Sons, New York, USA. pp: 85-86.
- Verster A, 1969. A taxonomic revision of the genus *Taenia linnaeus*, 1758 s. str. *Onderstepoort J Vet Res*, 36: 3-58.