

RESEARCH ARTICLE

Protective Effects of Naringenin on 5-Fluorouracil Induced Pulmonary Toxicity Via Modulation of NF- κ B and Nrf2 Pathway

Sravathi Vemula¹, Jeevanalatha Mylaram², Ravikumar Yadala¹, Gopalareddy Alla³, Anilkumar Banothu^{4*} and Hanuman Dunga Durga Veera⁴

¹Department of Veterinary Pathology, College of Veterinary Science, Rajendranagar, Hyderabad, Telangana, India.

²Department of Veterinary Pathology, College of Veterinary Science, Mamnoon-Warangal, Telangana, India.

³PV Narsimha Rao Telangana Veterinary University, Hyderabad, Telangana, India.

⁴Department of Veterinary Pharmacology and Toxicology, College of Veterinary Science, Rajendranagar, Hyderabad, Telangana, India.

*Corresponding author: anilvetpharma@gmail.com

ARTICLE HISTORY (23-272)

Received: July 15, 2023

Revised: October 16, 2023

Accepted: October 20, 2023

Published online: January 14, 2024

Key words:

5-Fluorouracil

Naringenin

Pulmonary toxicity

NF- κ B

Nrf-2

Oxidative stress

Anti inflammatory

ABSTRACT

5-Fluorouracil (FU) is an anti-cancer drug, most commonly used to treat solid malignancies across the globe, and Naringenin (NG) is a natural flavonoid with antioxidant properties. The present study was conducted on rats, which were divided into four groups to estimate the ameliorative effect of NG (100 mg/kg BW/day for 28 days- Group-3) against 5-FU-induced pulmonary toxicity (20 mg/kg BW/day-Group-2 for first 5 days). Group-1 rats were treated with normal saline, whereas group-4 rats were treated with the combination of both NG + 5-FU with same above protocol. During the subsequent period, six rats were sacrificed from each group on the 14th and 28th day of the experiment. Lung tissues were collected for various analyses like antioxidants profile, cytokine profile, histopathology, immunohistochemical and ultrastructure pathology. 5-FU-induced toxicity was characterized by a significant ($p < 0.05$) increase in TBARS in group 2, along with a significant ($p < 0.05$) reduction in GSH and SOD concentration on the 14th and 28th day of the experiment. Whereas, the combination group showed a significant decrease in thiobarbituric acid reactive substrate (TBARS) and increased GSH and SOD levels. Further, a significant ($p < 0.05$) increase in pro-inflammatory cytokines (TNF- α , IL-6, TGF- β and IL-1 β) along with a considerable ($p < 0.05$) lower level of IL-10 was observed in group 2 rats and significant improvement in all the parameters were observed in group-4 rats. In addition, on histopathological examination (HP), severe lung damage was observed along with oedema and mild fibrous tissue proliferation were noted which was further supported by scanning electron microscopy. Immunostaining of lung sections revealed strong positivity for NF- κ B, COX-2 and TNF- α expressions. However, treatment with NG exhibited a moderate decrease in the intensity of tissue damage observed in group 4 rats compared to group 2 rats. Overall, the intensity of toxicity was more evident on 28th day than 14th day in group 2 rats and a notable improvement in NG treatment of group-4 rats. Based on results, we suggested that NG had protective effects in ameliorating 5-FU-induced pulmonary toxicity.

To Cite This Article: Vemula S, Mylaram J, Yadala R, Alla G, Banothu A and Veera HDD, 2024. Protective effects of naringenin on 5-Fluorouracil induced pulmonary toxicity via modulation of NF- κ B and Nrf2 pathway. Pak Vet J, 44(1): 63-70. <http://dx.doi.org/10.29261/pakvetj/2024.126>

INTRODUCTION

Cancer is one of the second leading causes of death with the incidence of 19.3 million new cases and 10 million deaths across the world in the year 2020 (Ferlay *et al.*, 2020). 5-FU is the second most commonly employed

pharmaceutical agent and is categorized as an antimetabolite. It functions as a pyrimidine analog with a distinctive mechanism of action, primarily targeting the inhibition of thymidylate synthase (TS) enzyme activity. This action leads to a notable reduction in the synthesis of deoxyribonucleic acid (DNA), ribonucleic acid (RNA) and

subsequently protein synthesis. 5-FU is employed in the treatment of various solid tumors (Rashid *et al.*, 2014; Wigle *et al.*, 2019).

The common side effects of 5-FU are diarrhoea and numerous adverse effects like hematotoxicity (Sravathi *et al.*, 2022). Its adverse effects are mainly due to an increased superoxide anion (O_2^-) levels with reduced antioxidant enzymes. In addition, increased levels of lipid peroxidation (LPO), apoptosis, DNA damage and activation of pro-inflammatory cytokines (increased activity of Nuclear Factor kappa B (NF- κ B) protein levels) results in pulmonary toxicity (Gelen *et al.*, 2021).

Pulmonary toxicity associated with 5-FU mechanisms remains insufficiently investigated. It may result from severe emphysema, mononuclear cell infiltration (MNCs) and decreased surfactant release by damaged type-II pneumocytes, leading to alveolar wall destruction and intercellular accumulation of protein-rich edematous fluid. This, in turn, triggers the activation of inflammatory cytokines, primarily transforming growth factor beta 1 (TGF- β 1), a key mediator in lung tissue injury and a hallmark of pulmonary fibrosis, primarily *via* the NF- κ B signaling pathway (Fathy *et al.*, 2020; Alaaeldin *et al.*, 2022). The prolonged use of 5-FU may also cause pulmonary toxicity, but the extensive mechanism has not been studied yet. In this study, we explored the possible molecular mechanisms involved in pulmonary toxicity due to 5-FU, along with electron microscopy.

Natural products have a pool of phytochemicals, which provide a rich source of antioxidants (Priyanka *et al.*, 2020) and react actively against ROS (Ganaie *et al.*, 2019) and reactive nitrogen species (RNS) (Patel *et al.*, 2018). NG-4, 5, 7- trihydroxyflavanone is a natural flavonoid present in grapefruits, oranges, citrus fruit and tomatoes with ameliorative effects of therapeutic properties. Previous literature has shown that NG exhibits anti-oxidant, anti-inflammatory effects with cardioprotective and hepatorenal protective effects. It donates its hydrogen ions to hydroxyl free radicals to increase antioxidant assay along with increased expression of Nrf-2 pathway (Salehi *et al.*, 2019). Several studies have been performed to determine the protective mechanism of natural products against 5-FU-induced toxicity at different time courses (Yadav *et al.*, 2020) while no studies have been done on the impact of NG on 5-FU-induced pulmonary toxicity, with special emphasis on evaluating molecular mechanisms. Therefore, the present study aimed to explore the possible pulmonary protective mechanisms of NG by considering ultrastructural along with anti-inflammatory and antioxidants biomarkers against 5-FU-induced lung toxicity in rats.

MATERIALS AND METHODS

All chemicals were procured from SRL Private Limited, Hyderabad, India and 5-FU was obtained from celon laboratories private limited, Hyderabad.

Experimental design: The present experiment was carried out in forty-eight healthy albino Wistar male rats (200-250g) of 3 months age which were procured from Jeeva Life Science (ISO 9001:2015 certified company), Hyderabad. The experiment protocol was designed in line with the guidelines and started after permission was

granted by Institutional Animal Ethics Committee (No.9/24/C.V.Sc., Hyd. IAEC-Rats/ 12.06.2021). All rats were acclimatised for one week by maintaining hygienic conditions before beginning the experiment. In this study, adult male rats were divided into four groups, with twelve animals in one group. Group 1 rats treated as control received normal saline orally, group 2 received 5-FU alone at a dose rate of 20mg/kg b.wt, group 3 received NG (100mg/kg b.wt) orally for 28 days and group 4 rats were administered with 5-FU (@20 mg/kg b. wt/day) for 1st 5 days, NG at a dose rate of 100mg/kg b. wt/ day for 28 days, orally. Six animals from each group were sacrificed on the 14th and 28th day of the experiment. Further, lung samples were collected for different analyses. On the day of euthanization, bronchoalveolar fluid (BALF) fluid was collected. The study protocol was illustrated as a graphical representation in Fig. 2.

Bronchoalveolar lavage fluid collection (BALF): For intra-tracheal cannulation, we made a 2 cm incision on the trachea towards the ventral side and insinuated 2 mL of PBS into the lungs to collect and estimate the total cell count (cells/mL) and neutrophil counts (10^4 cells/mL) (Lee *et al.*, 2019).

Oxidative stress indices: A small chunk of lung tissue was collected and stored at -20^oC to study the organ antioxidant profiles, and the tissue was homogenized, followed by centrifugation to carry out all oxidative stress indices, measuring lipid peroxidation reaction through thiobarbituric acid reactive substrate (TBARS) (De Leon and Borges, 2020), reduced glutathione (GSH) concentration (Rahman *et al.*, 2006) and superoxide dismutase (SOD) assay (Weydert and Cullen, 2010).

Inflammatory cytokines estimation in lung homogenate: Specific inflammatory biomarkers were obtained using an Enzyme-linked immune sorbent assay (ELISA) kit from Genelia, Krishgen Biosystems (Mumbai) and followed the manufacturer kit protocol after homogenization of lung tissues. Colour Absorbance was measured at 450 nm immediately after the colour developed, and units were measured in pg/mg protein.

Histopathology (HP): For HP observation, we harvested the fresh small thin lung slices from euthanized rats and fixed them in 10% neutral buffer formalin for 48 hours and subjected to Washing, dehydration, clearing, sectioning and staining (Dey, 2023).

Immunohistochemistry (IHC): IHC was performed mainly in two steps-first, binding of 1^o antibodies from cell signalling technology to the interested antigen and detection of bounded antibody to the antigen of interest for immunoexpression of NF- κ B, Nrf2, TNF- α and COX-2 in the tissues of lung sections as per procedure given in the kit by Pathansitu, Biotechnologies, Hyderabad, India. Primary antibodies for NF-Kb (Cat. No. sc-8008), TNF- α (Cat. No. sc-52746), COX-2 (Cat. No. sc376861) and Nrf-2 (Cat. No. sc365949) were brought from Santa Cruz Biotechnology, USA. The intensity of immunoexpression under Light microscopic examination was visualised at 100x, modified procedure followed in our lab (Chelpuri *et al.*, 2022).

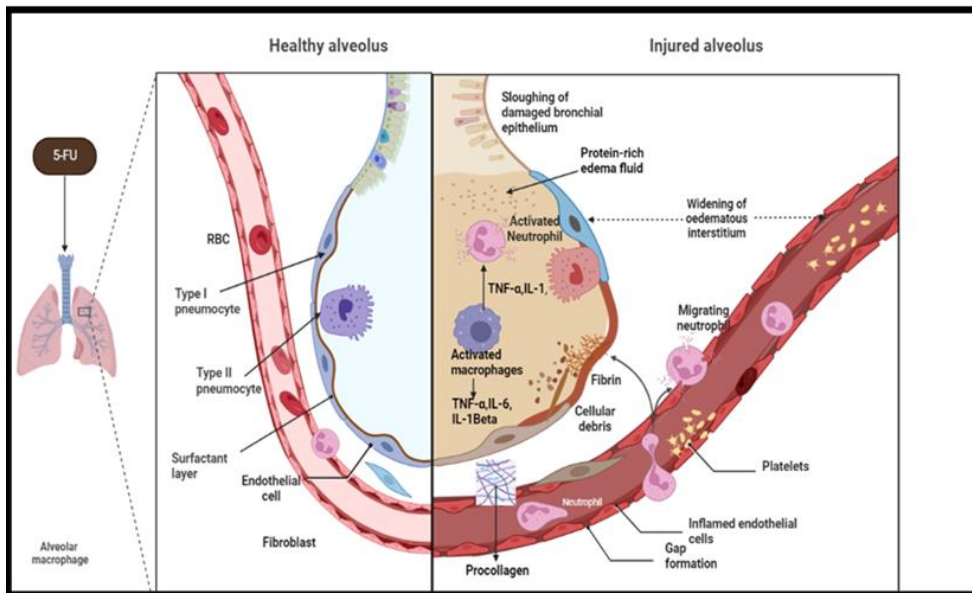


Fig. 1: Mechanism of action of 5-FU on lung injury. The figure illustrated pathogenesis caused by 5-FU in acute lung injury.

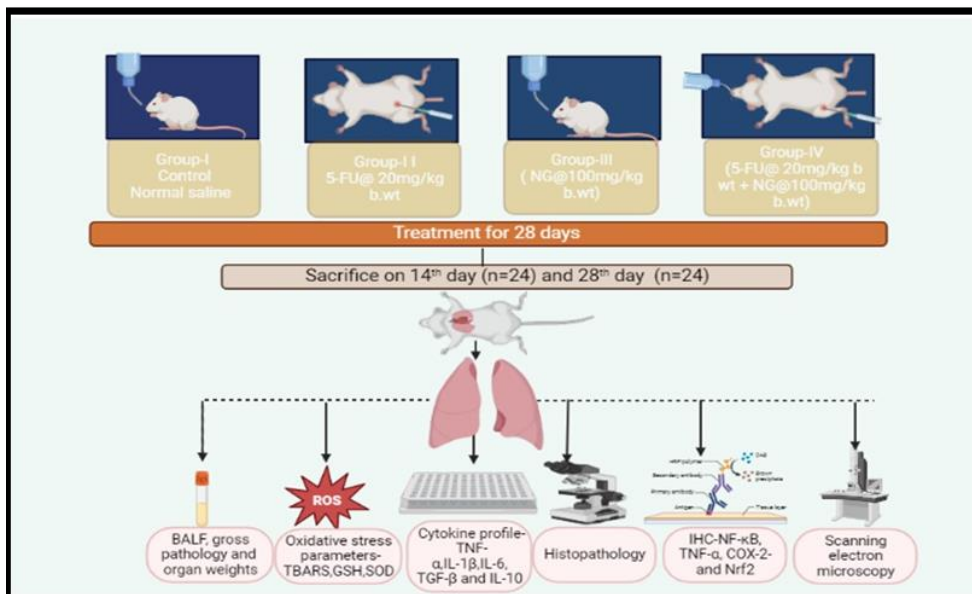


Fig. 2: Experimental design (BW: body weight, TBARS: Thiobarbituric acid reactive substances, GSH: glutathione, SOD: superoxide dismutase, TNF- α : Tumour necrosis factor, IL: interleukin, COX: cyclooxygenase, NF- κ B: Nuclear factor kappa beta, Nrf2: nuclear factor erythroid 2-related factor 2).

Effect of 5-FU on ultrastructural pathology: Immediately after sacrifice, tissues were dissected as thin slices ($1 \times 1 \text{ mm}^3$), fixed in 2.5 per cent glutaraldehyde kept at 4°C (pH 7.3) and followed the standard procedure of previous literature (Lakshman, 2017 and 2019) and observed under SEM (JSM-5600, Japan).

Statistical data analysis and Interpretation: The current studied data parameters were depicted as mean with standard error of measurements with six number of rats ($N=6$) in each group. Data obtained were exposed to one-way analysis of variance (ANOVA) applying statistical package for social sciences (SPSS) version 15.0, differences between mean values and significance level with consideration of statistical level of significance at $p < 0.05$ in each group (Snedecor and Cochran, 1994).

RESULTS

Effect of NG on BALF inflammatory cells: The inflammatory cells were determined to know the extent of inflammation caused by 5 FU, and this study reflected a

significant ($p < 0.001$) increase in total cell count (TCC), neutrophils and total leukocyte count (TLC) ($p < 0.001$) in rats treated with 5-FU. Whereas, the other treatment groups at different time intervals revealed significant improvement, suggesting an anti-inflammatory effect of NG, which has been given in Fig. 3A-C, compared with the toxic group (Table 1).

NG effect on oxidative stress parameters: The concentration of MDA was significantly increased while there was a decrease in the concentrations of ($p < 0.001$) in SOD and GSH in lung tissues homogenate of group 2. Conversely, a significant decrease in TBARS levels and significantly improved GSH and SOD levels in group-4 compared with group-2 rats suggesting that NG had an antioxidant potential of compound (Table-1).

Protective effect of NG on inflammatory cytokine storm: Sandwich ELISA was employed to assess pro-inflammatory cytokines (TNF- α , IL-6, TGF- β 1, IL-1 β) and the anti-inflammatory cytokine IL-10 in the lung tissue homogenates. The results revealed a significant ($p < 0.001$)

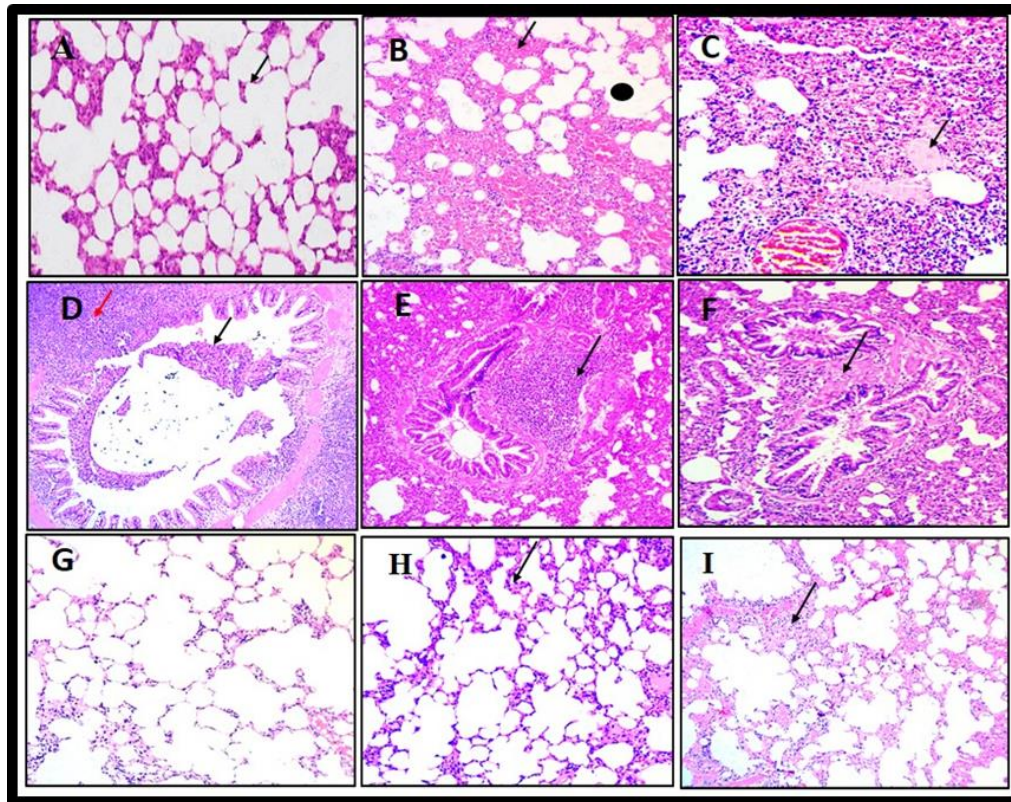


Fig. 3: Photomicrograph of histopathology of the lung (X 10): A: Lung of rat from G-I showing alveolar architecture with normal thin interalveolar septa. B: Lung of G-2 rat on day 14th showing mild to moderate pulmonary oedema, emphysema (arrow) with red hepatization (dot). C: Lung of G-2 rat on 14th day showing pulmonary oedema (arrow), congestion, haemorrhages in the interstitium with infiltration of MNCs and reduced alveolar spaces. D: lung of G-2 rat showing desquamation of bronchiolar epithelium lining from basal lamina, lumen partially filled with exfoliated cells (black arrow), severe infiltration of inflammatory cells (red arrow). E: lung of G-2 rat on 28th day showing thickening of the blood vessel with narrow lumen and BALF (arrow). F: lung of G-2 rat showing fibrosis in peribronchiolar area (arrow) and desquamation of bronchiolar epithelium lining from basal lamina. G: lung of G-3 rat showing alveolar architecture with normal thin interalveolar septa H: Lung of G-4 rat on 14th day showing mild infiltration of MNCs and mild emphysematous alveoli. I: Lung of G-4 rat on 28th day showing mild to moderate reconstructive appearance of alveolar epithelium and focal areas of infiltration of inflammatory cells (arrow). All sections were stained with H&E.

Table 1: BALF cytology, oxidative stress and inflammatory cytokines in different groups at different time intervals.

Parameters	Control		5-FU		NG		5-FU+NG	
	14 th Day	28 th Day	14 th Day	28 th Day	14 th Day	28 th Day	14 th Day	28 th Day
TLC (10 ⁹ /μl)	900.12±45 ^c	1500.2±0.55 ^c	2500.12±0.4 ^a	3340.11±0.4 ^a	895.23±0.2 ^c	1501.21±0.6 ^c	1800.42±0.67 ^b	2300.11±0.2 ^b
TNC (10 ⁴ cells/ml)	30.12±0.445 ^c	50.24±46 ^c	90.67±0.67 ^a	125.62±0.89 ^a	29.24±0.89 ^c	49.32±0.35 ^c	67.65±0.88 ^b	97.12±0.34 ^b
TCC (cells/ml)	500.05±54 ^c	800.46±0.37 ^c	1700.92±0.6 ^a	2500.21±0.5 ^a	499.21±0.3 ^c	798.11±35 ^c	1000.63±0.46 ^b	1800.1±0.23 ^b
TBARS (μM /mg of protein)	14.10±0.20 ^c	17.04±0.10 ^c	29.85±0.1 ^a	39.50±0.14 ^a	14.40±0.05 ^c	15.54±0.08 ^c	24.30±0.04 ^b	29.55±0.07 ^b
SOD (μM/mg protein)	8.43±0.04 ^a	7.94±0.05 ^a	4.32±0.34 ^c	3.92±0.33 ^c	8.40±0.44 ^a	7.90±0.52 ^a	5.09±0.03 ^b	5.15±0.13 ^b
GSH (μM/mg protein)	11.2±0.08 ^a	12.05±0.06 ^a	7.4±0.06 ^c	5.52±0.12 ^c	11.16±0.15 ^a	12.00±0.16 ^a	7.93±0.04 ^b	8.56±0.12 ^b
TNF-α (pg/mL)	106.21±0.3 ^c	116.55±0.93 ^c	147.11±0.76 ^a	166.21±0.72 ^a	105.11±0.6 ^c	116.12±0.52 ^c	126.11±0.1 ^b	138.45±0.22 ^b
IL-1β (pg/mL)	28.11±0.3 ^c	36.12±0.43 ^c	38.56±0.48 ^a	54.56±0.76 ^a	27.11±0.11 ^c	34.43±0.2 ^c	30.11±0.8 ^b	44.21±0.2 ^b
IL-6 (pg/mL)	17.09±0.43 ^c	23.12±0.4 ^c	32.14±0.11 ^a	43.16±0.75 ^a	17.21±0.1 ^c	23.82±0.7 ^c	22.43±0.1 ^b	28.36±0.71 ^b
TGF-β (pg/mL)	25.12±0.89 ^c	37.12±8 ^c	56.14±0.78 ^a	75.13±0.3 ^a	24.47±0.78 ^c	36.43±0.43 ^c	35.12±0.65 ^b	45.34±0.21 ^b
IL-10 (pg/mL)	44.12±0.5 ^a	53.67±0.1 ^a	23.11±0.37 ^c	27.16±12 ^c	43.12±0.27 ^a	52.11±0.1 ^a	33.12±0.23 ^b	42.67±0.56 ^b

Values are Mean ± SE (n=6); One-way ANOVA. Means with different superscripts in a column differ significantly at p<0.05 (*). BALF cytology (cells /mL): TLC-total cell count, TNC-total neutrophil count, TCC-total cell count, TNC-10⁴/mL. Oxidative stress parameters-μM/mg of protein, SOD-units/mg protein. Inflammatory cytokine profile and significant increase in anti-inflammatory cytokines (pg/mg) A) TNF-α B) IL-1β C) IL-6 D) TGF-β E) IL-1.

increase in pro-inflammatory cytokines. Conversely, there was a significant (p<0.001) decrease in the levels of IL-10, indicating that 5-FU induced a severe inflammatory response. Meanwhile, NG significantly reduced the pro-inflammatory cytokines in group-4 rats when compared with group-2 rats (Table-1).

Effect of NG on histopathology and lung injury score:

In the present experiment, lung microscopic lesions noticed in group 2 on 14th day included extravasation of erythrocytes into alveolar septa (red hepatization), thickened interstitium with infiltration MNCs, damage to alveoli, peribronchiolar infiltration of inflammatory

cells, lumen filled with exfoliated cells, peribronchiolar fibrosis with emphysema and oedema of alveoli. On the 28th day, profuse thickening of interstitium with MNCs (Grey hepatization), severe emphysema along with complete obliteration of lung alveoli, and fibrous tissue proliferation were observed and damaged epithelial cells are replaced by fibroblast in group-2 rats. At the same time, mild restorative structures were observed in NG treated group (Fig. 3A-I). A scorecard of lung tissue based on lesions is given in Table: 2. A-the score indicated a normal lung with normal architecture, ++ moderate lung injury and +++ indicated severe lung injury.

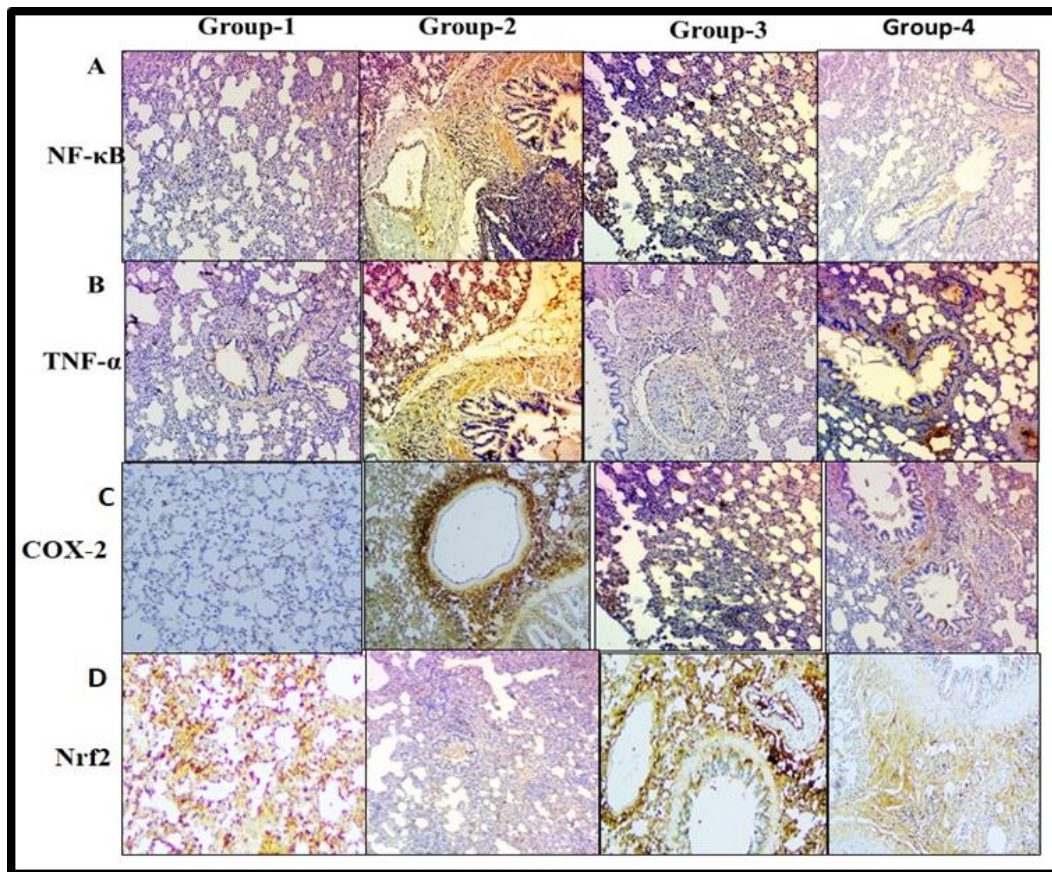


Fig. 4: Effect of NG on immunohistochemistry on lung tissues: A) NF-κB B) TNF-α C) COX-2 D) Nrf2.

Table 2: Table showing scoring of HP in lung tissue lesions and intensity of immunoexpression

Parameters	Group-1	Group-2	Group-3	Group-4
Congestion	-	+++	-	+++
Haemorrhages	-	+++	-	++
Exudation in alveoli and bronchioles	-	+++	-	++
Degenerations and necrosis in alveolar epithelium	-	+++	-	++
HP Infiltration of inflammatory cells in alveoli	-	++++	-	+++
Inflammatory odema	-	++++	-	++
Intensity of immunoexpression NF-κB	-	+++	-	++
TNF-α	-	+++	-	++
COX-2	-	+++	-	++
IHC Nrf2	+++	+	+++	++

Immunohistochemistry of lung tissue: Reduced immunoexpression of Nrf-2 in group-2 rats (Fig. 4D), along with an upregulated expression of NF-κB, TNF-α, and COX-2 (Fig. 4) was observed. In contrast, group-4 rats exhibited a significant upregulated expression of Nrf-2 and a decreased expression of NF-κB, TNF-α, and COX-2 concentrations through the NF-κB/Nrf2 signaling cascade molecular pathway (Fig. 4A-C). (Table 2).

Ultrastructural pathology: Scanned electron microscopy (SEM) of the lung sections of group 1 and group 3 rats revealed normal alveoli. The cut surface of group 2 rats in lung sections on day 14th revealed loss of architecture of the alveolar wall with mild thickened interstitium and mild fibrous tissue proliferation. Additionally, a few areas showed proliferating septa into the alveolar lumen with numerous blood cells in the alveolar septa. On the 28th day of the experiment, group 2 rats showed emphysematous alveoli, severe thickening of interstitium with narrow alveoli, mild infiltration of inflammatory cells along with erythrocytes, mild fibrous tissue proliferation with loss of

alveolar topography. Whereas, group 4 rats on the 14th and 28th day of the experiment showed mild infiltration of inflammatory cells with mild focal areas of the thickened interstitium in lung sections (Fig. 5A-K).

DISCUSSION

5-FU, the most used chemotherapeutic drug, prevents DNA and RNA synthesis. However, the toxicity of 5-FU limits its clinical usage. It interferes with this therapeutic efficacy and many studies have been conducted to demonstrate the protective benefits of certain medicines against 5-FU-induced toxicity (Gelen *et al.*, 2021). Naringenin is a phytochemical flavonoid compound with a rich source of antioxidants, primarily found in tomatoes, grapes and oranges and has promising protective effects against various toxicities (Naraki *et al.*, 2021). The current study revealed that rats in the toxic group displayed a marked deterioration in lung injury. However, limited literature regarding NG against 5-FU-induced pulmonary toxicity at different time intervals is available.

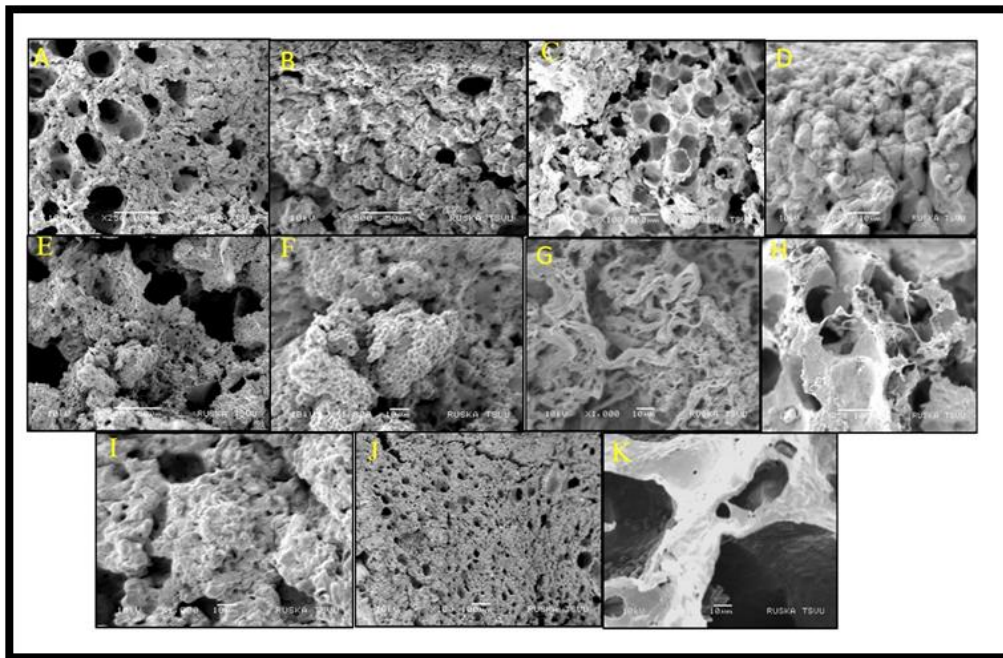


Fig. 5: Scanning electron micrograph of lung section showing normal alveolar septa with normal epithelial cells in alveoli. B. Lung section of G-2 rat on 14th day showing thickened interstitium and loss of alveolar architecture. C: Lung section of G-2 rat on 14th day showing emphysematous alveoli with thin alveolar walls. D: Lung section of G-2 rat on 14th day showing mild fibrous tissue proliferation. E: Lung section of G-2 rat on 28th day showing proliferating alveolar septa into alveolar lumen. F: Lung slice of G-2 on 28th day showing numerous blood cells in alveolar septa. G: Lung section of G-2 rat on 28th day showing alveolar septa with fibrous tissue proliferation H: lung section of G-2 rat on 28th day showing emphysematous alveoli and fibrous tissue proliferation with collapsed alveolar structure. I&J: Lung section of G-4 rat on 14th day showing mild restoration of the normal architecture of alveoli. K: Lung section of G-4 rat on 28th day showing endothelium lining with erythrocytes indicating improvement in tissue restoration.

In the current study of BALF (Broncho alveolar lavage fluid) smears, we found that 5-FU increase in total cell count indicates the process of inflammation and activation of neutrophils for favouring of inflammation. Whereas treatment with NG decreased total cell count and suggested anti-inflammatory properties. These results were in accordance with previous reports (Hsieh *et al.*, 2018). 5-FU-induced injury could be activating the NF- κ B transcription factor by modulating the expression of many genes, resulting in the collapse of the basement membrane, and further leading to lung injury (Arab *et al.*, 2018). In the present study, 5-FU induced pulmonary toxicity due to the upregulation of lipid peroxidation with a compensatory reduction in antioxidant parameters (SOD and GSH) levels in the treatment group. These observations were concurrent with the previous study (Rashid *et al.*, 2013). NG might exhibit the properties of scavenging free radicals with increasing the expression of glutamyl cysteine ligase, thus terminating oxidative damage lung injury (Naraki *et al.*, 2021; Namratha *et al.*, 2021).

A significant increase in the production of inflammatory cytokines through Janus kinase/signal transducer and activator of transcription (JAK/STAT) pathway transduces signals for a wide variety of cytokines (Refaie *et al.*, 2022). It also induces alveolar epithelial apoptotic cell death which is considered a major perpetuating step in the pathological cascade of lung fibrosis in BLM-induced pulmonary fibrosis (Turgut *et al.*, 2016), which might be the exact reason for 5-FU pulmonary toxicity. In the current study, we assessed a significant ($p < 0.05$) elevation in the concentration of pro-inflammatory cytokines and a substantial decrease in IL-10 in homogenized tissue of group 2 rats might occur due to 5-FU ability to cause excessive ROS generation, which

stimulates multiple signalling pathways mostly through TGF- β (Fan *et al.*, 2001) including the redox-sensitive NF- κ B transcription and MAPK pathway and ultimately resulting in various gene expressions for inflammatory cytokines (Elghareeb *et al.*, 2021). These results were in accordance with the reports of Renushe *et al.* (2022) and Maimonaparveen *et al.* (2021), who demonstrated the inflammatory effects of vincamine against LPS-induced acute lung injury and pomegranate juice against belomycin-induced lung toxicity. Treatment with NG mitigated the LPO interstitial fibrosis (Zhang *et al.*, 2015) and decreased inflammatory markers by interactions with intracellular signalling cascades *via* stimulation of Nrf-2 and Akt activation, thus reducing phosphorylation of ERK1/2, P38 MAPK, Akt and Caspase-3 to suppress apoptosis and NF- κ B Toll-like receptor 4 (TLR4) stimulation, thus inhibiting pro-inflammatory cytokines gene expression and also alleviated inflammatory responses possibly via increasing peroxisome proliferator-activated receptor- γ (PPAR γ) expression (Karuppagounder *et al.*, 2015) (Fig. 6).

In the present experiment, noteworthy lung lesions were noticed in group 2 on the 14th day and 28th day due to damaged epithelial cells being replaced by fibroblast due to oxidative stress through the NF- κ B signalling pathway, direct cellular damage and inadequate production of surfactant by pneumocytes, type II (Da Silva *et al.*, 2023) which play an essential role in 5-FU induced pulmonary toxicity (Al-Hamdany and Al-Hubaity, 2014). In the present study, the lung sections of group 4 rats on day 14th and 28th day showed mild thickened interstitium and infiltration of inflammatory cells, but due to regular uptake of NG on 28th day, moderate reconstructive appearance of alveolar epithelium and decreased extravasation of erythrocytes.

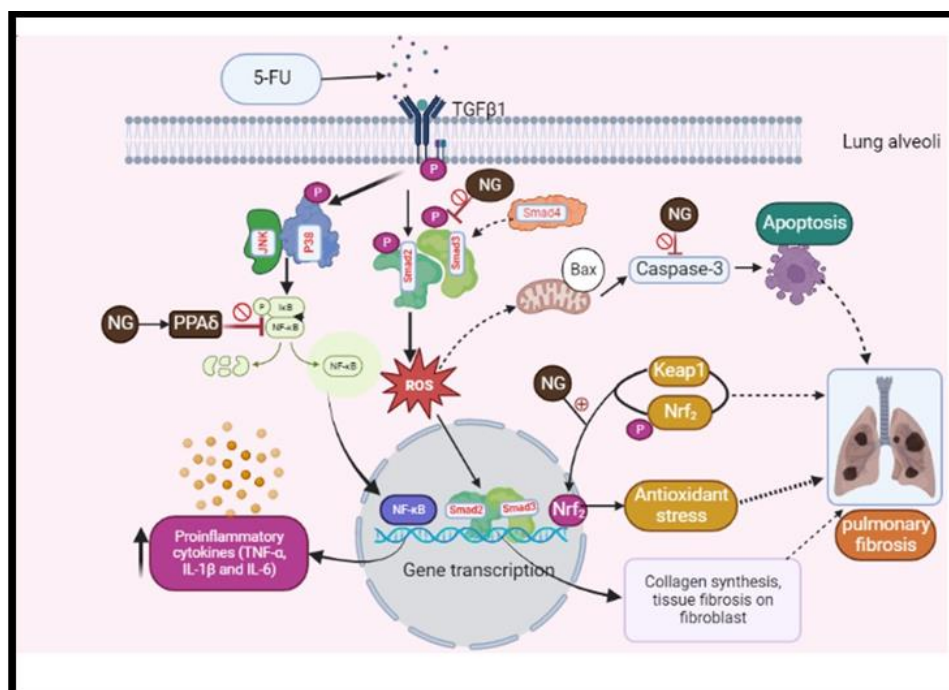


Fig. 6: Schematic diagram of ameliorative effect of NG on 5-FU induced pulmonary toxicity.

We further studied the ameliorative effects of NG by performing the immunohistochemical technique. We found a significant increase in the immunoexpression of molecular proteins like TNF- α , NF- κ B and COX-2 with considerable downregulation of Nrf2 expression (Huang and Wang 2017 and Shie *et al.*, 2015). Hence, we inferred that NG has anti-inflammatory properties and antioxidant properties as elucidated by Nrf2 pathway (De Oliveira *et al.*, 2018).

In addition to understanding at the ultrastructural level, SEM was also performed. Ultrastructurally (SEM), the cut surface of group 2 rats showed lung damage due to fibrous tissue proliferation and these changes were mild and improved in the NG treated group 4 rats which might be due to potential anti-oxidant and anti-inflammatory potential of NG (Chin *et al.*, 2020). Based on the above findings the present study results speculated that NG had intense protective action of antioxidant and anti-inflammatory properties by increasing Nrf2 expression and down regulated NF- κ B protein expressions, thus reducing moderate tissue damage on the 28th day of the experiment. The possible schematic mechanism of action of NG was illustrated in Fig. 6.

Conclusion: In conclusion, this experimental study demonstrated that NG has ameliorative effects against 5-FU-induced pulmonary toxicity which was evidenced by a significant decrease in oxidative stress, a reduction in the inflammatory cytokine storm, inhibitory immunoexpression of NF- κ B, an upregulation of the Nrf2 expression pathway, and restoration of antioxidant potential. These findings indicated the protective effects of NG against 5-FU on both the 14th and 28th days. However, on the 28th day, the intensity of tissue injury by 5-FU was higher than on the 14th day of the experiment in rats. Similarly, NG also exhibited greater ameliorative efficacy after 28 days when compared with the 14th day in the treatment groups. Further studies may be required to understand the bioavailability of NG and its therapeutic efficacy.

Authors Contribution: Sravathi Vemula has been involved in conducting experimental studies and lab analysis of work. Jeevanalatha Mylaram helped in the experimental design. Ravikumar Yadala has collected literature and arranged chemicals in the laboratory analysis. Gopalarreddy Alla acted as monitoring and supervision of the work progress. Anilkumar Banothu assisted in lab analysis, statistical analysis and preparation of manuscripts and acted as the overall supervisor of work. Hanuman Dunga Durga Veera assisted in lab work and conducting animal studies.

REFERENCES

- Alaaeldin R, Ali FE, Bekhit AA, *et al.*, 2022. Inhibition of NF- κ B/IL-6/IAK2/STAT3 pathway and epithelial-mesenchymal transition in breast cancer cells by azilsartan. *Mol* 27:7825-7830.
- Al-Hamdany MZ and Al-Hubaity AY, 2014. Protective Effects of N-acetylcysteine against 5-Fluorouracil-Induced Pulmonary Toxicity in Albino Rats. *Iraqi J Med Sci* 12:2-4.
- Arab HH, Salama SA and Maghrabi IA, 2018. Camel milk ameliorates 5-fluorouracil-induced renal injury in rats: targeting MAPKs, NF- κ B and PI3K/Akt/eNOS pathways. *Cell Physiol Biochem* 46:1628-42.
- Chelpuri Y, Shivakumar P, Gopala R, *et al.*, 2022 "Tropolone derivative hinokitiol ameliorates cerulein-induced acute pancreatitis in mice." *International Immunopharmacology* 109: 108915.
- Chin LH, Hon CM, Chellappan, *et al.*, 2020. Molecular mechanisms of action of naringenin in chronic airway diseases. *Eur J Pharmacol* 8:31-9.
- Da Silva MC, Fabiano LC, da Costa Salomao KC, *et al.*, 2023. A rodent model of Human-Dose-Equivalent 5-Fluorouracil: Toxicity in the liver, kidneys and lungs. *Anti* 12:1005.
- De Leon JA and Borges CR, 2020. Evaluation of oxidative stress in biological samples using the thiobarbituric acid reactive substances assay. *J Vis Exp* 12:e61122.
- De Oliveira MR, Andrade CM and Furstenau CR, 2018. Naringenin exerts anti-inflammatory effects in paraquat-treated SH-SY5Y cells through a mechanism associated with the Nrf2/HO-1 axis. *Neurochem Res* 43:894-903.
- Dey P, 2023. Tissue Microtomy: Principle and Procedure. In *Basic and Advanced Laboratory Techniques in Histopathology and Cytology* 1st edn, Springer, Singapore, 41-50.
- Elghareeb MM, Elshopekey S and Lashen S, 2021. Synergistic effects of Ficus Carica extract and extra virgin olive oil against oxidative injury, cytokine liberation, and inflammation mediated by 5-

- Fluorouracil in cardiac and renal tissues of male albino rats. *Environ Sci Pollut Res* 28:4558-4572.
- Fan J, Ye RD and Malik AB, 2001. Transcriptional mechanisms of acute lung injury. *Am J Physiol Lung Cell Mol Physiol* 281:1037-1050.
- Fathy M, Okabe M, Saad Eldien HM, et al., 2020. AT-MSCs antifibrotic activity is improved by eugenol through modulation of TGF- β /Smad signaling pathway in rats. *Mol* 25:348.
- Ferlay J, Ervik M, Lam F, et al. 2021. Global Cancer Observatory: Cancer Tomorrow. Lyon: IARC 2020.
- Ganaie MA, Jan BL, Khan TH, et al., 2019 The protective effect of naringenin on oxaliplatin-induced genotoxicity in mice. *Chem Pharm Bull* 67:433-438.
- Gelen V, Sengul E, Yildirim, et al., 2021. The protective effects of hesperidin and curcumin on 5-fluorouracil-induced nephrotoxicity in mice. *Environ Sci Pollut Res* 28:47046-47055.
- Huang H and Wang Y, 2017. The protective effect of cinnamaldehyde on lipopolysaccharide induced acute lung injury in mice. *Mol Cell Biol* 63:58-63.
- Hsieh YH, Deng JS, Chang YS, et al., 2018. Ginsenoside Rh2 ameliorates lipopolysaccharide-induced acute lung injury by regulating the TLR4/PI3K/Akt/mTOR, Raf-1/MEK/ERK, and Keap1/Nrf2/HO-1 signaling pathways in mice. *Nutrients* 10:1208-1215.
- Karuppagounder V, Arumugam S, Thandavarayan RA, et al., 2015. Naringenin ameliorates daunorubicin induced nephrotoxicity by mitigating AT1R, ERK1/2-NF κ B p65 mediated inflammation. *Int Immunopharmacol* 28:154-159.
- Lakshman M, 2017. Diagnostic Electron Microscopy (EM) for Avian Diseases-An Overview. *Int J Sci Res* 6:1478-1483.
- Lakshman M, 2019. Application of conventional electron microscopy in aquatic animal disease diagnosis: A review. *J Entomol Zool Stud* 7:470-475.
- Lee AMS, Lee SH, Kim JY, et al., 2019. Effects of glycyrrhizin on lipopolysaccharide-induced acute lung injury in a mouse model. *J Thorac Dis* 11:1287-1292.
- Maimonaparveen S, Madhuri D, Lakshman M and Anilkumar B, 2021. Anti-inflammatory Potential of Whole Pomegranate Fruit Juice (POM) against Bleomycin Induced Lung Injury in Rats. *J Anim Res* 6: 989-993.
- Namratha ML, Lakshman M, Jeevanalatha M, et al., 2021. Assessment of Vitamin C Protective Activity in Glyphosate-Induced Hepatotoxicity in Rats. *Pakistan Veterinary Journal* 41:439-445.
- Naraki K, Rezaee R and Karimi G, 20. A review on the protective effects of naringenin against natural and chemical toxic agents. *Phytother Res* 35:4075-4091.
- Patel K, Singh GK and Patel DK, 2018. A review on pharmacological and analytical aspects of naringenin. *Chin J Integr Med* 24:551-560.
- Priyanka G, Anil Kumar B, Lakshman M, et al., 2020. Adaptogenic and immunomodulatory activity of Ashwagandha root extract: An experimental study in an equine model. *Front Vet Sci* 7:541112.
- Rahman I, Kode A and Biswas SK, 2006 Assay for quantitative determination of glutathione and glutathione disulfide levels using enzymatic recycling method. *Nat Protoc* 6:3159-65.
- Renushe AP, Banothu AK, Bharani KK, et al., 2022. Vincamine, an active constituent of *Vinca rosea* ameliorates experimentally induced acute lung injury in Swiss albino mice through modulation of Nrf-2/NF- κ B signaling cascade. *Int Immunopharmacol* 108:108773.
- Rashid S, Ali N, Nafees S, et al., 2013. Abrogation of 5-fluorouracil induced renal toxicity by bee propolis via targeting oxidative stress and inflammation in Wistar rats. *J Pharm Res* 7:189-194.
- Rashid S, Ali N, Nafees S, et al., 2014. Mitigation of 5-Fluorouracil induced renal toxicity by chrysin via targeting oxidative stress and apoptosis in wistar rats. *Food Chem Toxicol* 66:185-193.
- Refaie MM, Shehata S, Bayoumi AM, et al., 2022. The IL-6/STAT signaling pathway and PPAR α are involved in mediating the dose-dependent cardioprotective effects of fenofibrate in 5-fluorouracil-induced cardiotoxicity. *Cardiovasc Drugs Ther* 36:817-827.
- Salehi B, Fokou PV, Sharifi-Rad M, et al., 2019. The therapeutic potential of naringenin: a review of clinical trials. *J Pharm* 12:11-15.
- Shie PH, Huang SS, Deng JS, et al., 2015. *Spiranthes sinensis* suppresses production of pro-inflammatory mediators by down-regulating the NF- κ B signaling pathway and up-regulating HO-1/Nrf2 anti-oxidant protein. *Am J Chinese Med* 43:969-89.
- Snedecor G and Cochran W, 1994. Statistical methods. 8th edn East West Press Pvt. Ltd., New Delhi, India 313.
- Sravathi V, Jeevanalatha M, Ravikumar Y, et al., 2022. 5-Fluorouracil induced hematological alterations in wistar rats and its amelioration with naringenin. *J Pharm Innov* 12:1-6.
- Turgut NH, Kara H, Elagoz S, et al., 2016. The protective effect of naringin against bleomycin-induced pulmonary fibrosis in Wistar rats. *Pulm Med* 14:12-19.
- Weydert CI and Cullen II. 2010. Measurement of superoxide dismutase, catalase and glutathione peroxidase in cultured cells and tissue. *Nat Protoco* 5:51-66.
- Wigle TJ, Tsvetkova EV, Welch SA, et al., 2019. DPYD and fluorouracil-based chemotherapy: Mini review and case report. *Pharma* 11:199-201.
- Yadav M, Sehrawat N, Singh M, et al., 2020. Cardioprotective and hepatoprotective potential of citrus flavonoid naringin: Current status and future perspectives for health benefits. *Asian J Biol Sci* 9:1-5.
- Zhang N, Yang Z, Yuan Y, et al., 2015. Naringenin attenuates pressure overload-induced cardiac hypertrophy. *Exp Ther Med* 10:2206-2212.