



RESEARCH ARTICLE

Evaluation of Toxic Effects of Silver Micro and Nanoparticles and Silver Nitrate in Crayfish (*Astacus leptodactylus*)

I Şimsek^{1*}, P Arslan Yuce², G Gul³, A Ç Gunal⁴, O Kuzukiran¹ and A Filazi⁵

¹Çankırı Karatekin University, Şabanözü Vocational School, Çankırı, Turkey; ²Çankırı Karatekin University, Faculty of Science, Department of Biology, Çankırı, Turkey; ³Gazi University, Vocational School of Health Services, Ankara, Turkey; ⁴Gazi University, Faculty of Gazi Education, Department of Biology Education, Ankara, Turkey; ⁵Ankara University, Faculty of Veterinary Medicine, Department of Pharmacology and Toxicology, Ankara, Turkey

*Corresponding author: ilkers@karatekin.edu.tr

ARTICLE HISTORY (25-387)

Received: April 26, 2025
Revised: July 24, 2025
Accepted: July 27, 2025
Published online: August 11, 2025

Key words:

Biochemistry
Crayfish
Histopathology
Micro Silver
Nano Silver
Silver Nitrate

ABSTRACT

Silver exists in nature both as compounds, such as silver nitrate (AgNO_3), and in particulate forms including microparticles and nanoparticles. Due to its widespread use in industries such as cosmetics and textiles, silver poses potential risks to both environmental and human health. This study aimed to evaluate the toxic effects of different silver forms on freshwater crayfish. For this purpose, the 48-hour sublethal effects of 0.1 and 1mg/L concentrations of AgNO_3 , silver microparticles (AgMPs), and silver nanoparticles (AgNPs) were assessed based on hemolymph parameters, tissue biochemistry, and histopathological alterations. A considerable reduction in total hemocyte count was observed in crayfish exposed to AgNO_3 . Biochemical responses in gill and hepatopancreas tissues varied depending on the type of silver compound administered. Histopathological analysis revealed no notable alterations in the antennal gland, muscle, gonads, heart, or digestive system across all treatment groups. However, exposure to AgNO_3 led to lamellar degeneration, hemocytic infiltration, and epithelial hyperplasia in the gills. Moreover, tissue damage severity in gill and hepatopancreas varied according to the particle size of the silver material. These findings suggest that silver-based substances, particularly in nanoparticulate forms, should be carefully examined for their potential ecological risks. Differences in particle size may result in varying degrees of toxicity in aquatic organisms.

To Cite This Article: Şimsek I, Arslan Yuce P, Gul G, Gunal AÇ, Kuzukiran O and Filazi A 2025. Evaluation of toxic effects of silver micro and nanoparticles and silver nitrate in crayfish (*Astacus leptodactylus*). Pak Vet J, 45(3): 1389-1395. <http://dx.doi.org/10.29261/pakvetj/2025.218>

INTRODUCTION

Freshwater crayfish are one of the most favourable bioindicators among invertebrates due to their large size, long life span and dependence on water systems throughout their lives (Zarnescu *et al.*, 2017). Therefore, their biological responses to environmental pollution can mirror the health situation of aquatic ecosystems (Banaee *et al.*, 2019; Uçkun, 2022). Crayfish are ecologically important, highly adaptable benthic omnivores characterized by solitary behavior, high fertility, short generation times, and juvenile care—traits that contribute to their suitability as bioindicators (Tunca *et al.*, 2013). Owing to their intermediate trophic level, crayfish can act as vectors for transferring toxins and pollutants to higher trophic organisms within aquatic ecosystems (Zarnescu *et al.*, 2017). Among these, the narrow-clawed crayfish (*Astacus leptodactylus*) serves as a prominent species. It is found in

freshwater in Asia and Europe; it can also naturally adapt to different water bodies and estuarine conditions (Harhoğlu, 2004; Benli, 2014). *Astacus leptodactylus* has an economic value as it is the only native freshwater crayfish in Türkiye and is regularly exported (Uçkun, 2022; Dirican, 2025).

Silver (Ag) exhibits chemical inertness, aqueous solubility, and undergoes oxidation under atmospheric conditions (Ferdous and Nemmar, 2020). Toxicological studies across diverse biological systems demonstrate size-dependent cytotoxicity of Ag particles, with distinct mechanistic differences observed between microscale and macroscale contaminants (Reilley *et al.*, 2023). A primary toxicological pathway for microparticles involves their capacity to induce reactive oxygen species (ROS) generation, while particulate morphology further modulates cytotoxic outcomes (Golokhvast *et al.*, 2015; Zhai *et al.*, 2016).

Nanoparticles (NPs), classified as materials with at least one dimension between 1-100nm (Sati *et al.*, 2025), possess unique physicochemical characteristics including nanoscale dimensions, enhanced surface area-to-volume ratios, elevated reactivity, transport capabilities, and modifiable surface functionalities (Sharma *et al.*, 2025). Silver nanoparticles (AgNPs) have achieved particular prominence due to their broad-spectrum antimicrobial activity and redox modulation properties (Auclair *et al.*, 2021). Current industrial applications span 15 commercial sectors, encompassing water treatment technologies, antimicrobial coatings, dermal formulations, smart textiles, active food packaging, nanoelectronics, and biomedical devices (Ale *et al.*, 2019; Calisi *et al.*, 2022; Şimşek *et al.*, 2024). Annual global production exceeds 320 metric tons of nanosilver to satisfy escalating commercial demands (Ferdous and Nemmar, 2020).

However, the rapid expansion of nanotechnology has raised environmental and health concerns, particularly regarding the ecotoxicological implications of nanoparticle exposure (Cote *et al.*, 2014; Auclair *et al.*, 2021). Ongoing scientific debate focuses on whether nanoparticles present greater ecological risks than their bulk or ionic counterparts (Calisi *et al.*, 2022). Despite their widespread use, no fully effective methods currently exist to remove or neutralize NPs in environmental systems (Li *et al.*, 2025). Improper disposal of AgNP-containing consumer products is believed to contribute significantly to silver loads in wastewater effluents (Auclair *et al.*, 2021). As a result, increasing environmental release of AgNPs is expected, heightening exposure risks for aquatic biota. Silver is known to be toxic to both freshwater and marine species and is characterized by its environmental persistence and high bioaccumulation potential in water, sediments, and organisms (Gomes *et al.*, 2014). The environmental behavior of AgNPs, particularly dissolution kinetics, aggregation patterns, and precipitation dynamics, constitutes critical determinants of their bioavailability and ecotoxicological profiles in marine ecosystems (Calisi *et al.*, 2022). Empirical evidence demonstrates significant bioaccumulation of silver particles across trophic levels, with elevated tissue concentrations documented in marine biota (Cote *et al.*, 2014). Such bioaccumulative persistence transitions nanoparticle contamination into a potent ecological threat, particularly in benthic and pelagic food webs (Pandiarajan and Krishnan, 2017).

This study investigates the comparative toxicological impacts of particulate silver (nanoscale, microscale) and ionic silver (AgNO₃) exposures on *Astacus leptodactylus* (narrow-clawed crayfish), a keystone freshwater decapod species serving as a bioindicator for aquatic ecotoxicity assessments.

MATERIALS AND METHODS

Chemicals and Reagents: AgNPs, (purity >99,99% and 18nm size, shape of AgNPs were spherical and crystal structure was cubic) and silver microparticles (AgMPs), (purity >99,99% and 3µm size, melting temperature: 960.8°C, boiling temperature: 2210°C, density: 10.491g/cm³, form: powder) were purchased from Nanografi Nano Technology (Ankara, Turkey). Silver nitrate was purchased from Merck (Darmstadt, Germany).

Test organism maintenance: A total of 49 narrow-clawed crayfish *Astacus leptodactylus* (mean length 12.34±0.9cm and mean weight 60.2±12.9g) were caught from Eğirdir Lake (Isparta, Turkey) during the intermolt period and fishing season and brought to laboratory in humified conditions. The specimens were maintained in 80L aquaria with continuous aerated and dechlorinated tap water. Prior to experimentation, the animals were maintained under standardized laboratory conditions for a period of four weeks to allow for acclimatization. During the acclimation period, the aquaria water was renewed every two days to remove the metabolic waste and to keep water physicochemical parameters (mean temperature 20.2±1.5°C; mean dissolved oxygen 5.24±1.2mg/L; mean conductivity 220.1±0.9µS/cm; mean Ph 7.52±0.42). The specimens were fed *ad libitum* with raw trout until the 24h before the exposure experiments. The model organism for this study is an invertebrate. Therefore, this study did not require ethics committee approval according to Turkish Laboratory Experiment Regulations. Welfare conditions and experiments were conducted in accordance with the Guide for the Care and Use of Laboratory Animals (NIH Publication No. 85–23, revised 1996) published by the US National Institutes of Health and guidelines for the care of laboratory invertebrates.

Chemicals exposure: After acclimation period, all 49 specimens were randomly divided into seven aquaria (7 animals per aquaria (1animal/L)). The animals were exposed to two concentrations (0.1 and 1mg/L) of AgNO₃, AgMPs, and AgNPs. A control group was maintained in aquarium water without any chemical treatment. The dosage was chosen according to Struzynski *et al.* (2013). Following a 48-hour exposure period, animals from all groups were sampled under ice anesthesia. Hemolymph was collected for total hemocyte count analysis, while gill and hepatopancreas tissues were excised and preserved for subsequent analyses.

The total hemocyte counts: The hemolymph tissue was taken from the second walking limb of crayfish using sterile syringe. The hemolymph samples were diluted and fixed with 4% formalin (1:1,v:v). Then, the hemocytes were counted using Thoma chamber under the light microscope and the total hemocyte counts (THCs) were assessed accordingly Yavuzcan and Benli (2014).

Oxidative stress assays: The oxidative stress analysis was conducted on dissected gills and hepatopancreas of each animal and the dissected tissues were homogenized using ultraturax homogenizer (Eschau, Germany). All biochemical parameters employed in this study were colorimetric and followed by the protocols shown in (Table 1).

The procedure of histopathology: Gill and hepatopancreas tissues underwent fixation in Davidson's solution, followed by a graded ethanol dehydration protocol (70, 80, 90, 96%, and anhydrous ethanol) and xylene-mediated clearing. Tissue samples were subsequently embedded in paraffin-embedded tissue blocks and sectioned at 5µm thickness using a rotary microtome. Sections were subjected to histological staining

Table 1: The biochemical analysis procedure

Parameter	Procedure	Reference
AOPP	100µL supernatant sample [previously homogenized in 400µL Tris-HCl buffer (20mM, pH: 7.4) and centrifuged for 10min. at 5000rpm. at +4°C] 400µL phosphate buffer solution (PBS, 1M pH:7.4) was diluted. Then, 10µL potassium iodide (KI) and 20µL Sarsat et acetic acid were added to the diluted samples. After vortexing this mixture, the absorbance was determined at 340nm against a blank containing PBS. Tissue AOPP amounts were determined using Chloramine T (CAS number: 7080-50-4) at levels of 5, 10, 20, 40, 80 and 100µM as standard. Tissue protein determination was measured by the Mihara and Uchiyama, (1978) method using bovine serum albumin standards from the supernatant sample. AOPP levels of tissues were shown as µM AOPP/mg protein.	Witko-1996
GSH	200µL supernatant sample [previously homogenized in 900µL metaphosphoric acid (0.5M, pH:8) and centrifuged for 10min. at 3500 rpm. at +4°C] was mixed 2,8 mL Ellman reagent. The absorbance was determined at 410 and 420nm against a blank containing reaction mixture only. Tissue GSH amounts were determined using glutathione (CAS number:70-18-8) whose standard levels of 5, 10, 25, 50, 75, and 100µM as standard. Tissue protein determination was measured by the Bradford method using bovine serum albumin standards from the supernatant sample. The GSH levels of tissues were shown as µM GSH/mg protein.	Ellman, 1959
MDA	500µL of homogenate sample [previously homogenized with 900µL of 1.15% Potassium chloride (KCl)] was mixed with 3mL Mihara and of 1% phosphoric acid and 1mL of 0.6% thiobarbituric acid. After cooling, 4 mL n-butanol was added to the samples that were kept in a 60°C water bath for 45min. and mixed. Supernatants taken from the samples centrifuged at 3000rpm for 5min. were read at 520 and 535nm absorbance. MDA levels of tissues were shown as nM/mg tissue.	Mihara and Uchiyama, 1978

using Mayer's hematoxylin and eosin Y (H&E) for cellular visualization. Histological preparations were analyzed via brightfield microscopy, with representative fields digitally imaged for documentation. Histomorphological assessments were conducted in accordance with standardized semiquantitative scoring criteria established by Benli *et al.* (2008), focusing on tissue-specific pathological markers. According to Benli *et al.* (2008) method, "the criterion of the histopathological alteration of the tissues was scored according to the intensity of the lesions as* (-) none (no histological alterations), which represents normal histological structure; (+) histopathology in >20% of fields (mild); (++) histopathology in 20-60% of fields (moderate) and (+++) histopathology in <60% of fields (severe)".

Statistical analysis: Statistical analyses were executed utilizing GraphPad Prism 5.0. Normality distribution was verified through the Shapiro-Wilk test. Parametric comparisons of experimental groups were performed via one-way analysis of variance (ANOVA). After using one-way ANOVA, the statistical significance between groups was evaluated by Tukey analysis with statistical significance determined at $P \leq 0.05$.

RESULTS

Within the scope of the study, no deaths were observed in the groups during the 48h exposure periods.

The alterations in Total Hemocyte Counts (THCs) exposed to silver particles: The THCs in narrow-clawed freshwater crayfish exposed to silver substance derivatives (AgNO_3 , AgMPs and AgNPs) stress for 48h was significantly lower than in the control groups (Fig. 1).

Advanced Oxidative Protein Products (AOPPs): In the gill tissues of narrow-clawed freshwater crayfish exposed to AgNO_3 for 48h, a rapid decrease in advanced oxidative protein product (AOPP) values was observed at low concentration, while an increase was shown at higher concentration. In the groups exposed to AgMPs and AgNPs, there was a decrease in AOPP values at low concentrations (Fig. 2).

Total glutathione: As a result of exposure of narrow-clawed freshwater crayfish to 0.1mg/L AgNO_3 for 48 h,

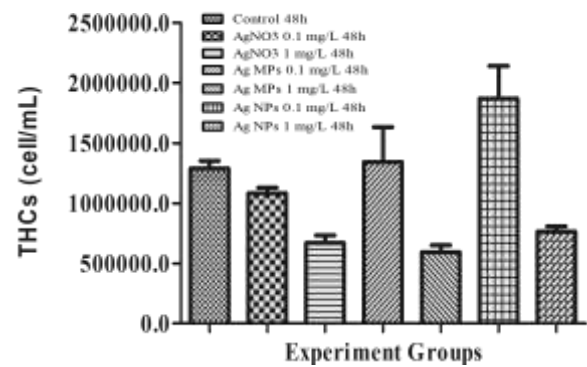


Fig. 1: Detection on THCs of narrow-clawed freshwater crayfish from silver derivatives exposure group and control group. The bars represented the mean \pm SE * indicate $P < 0.05$.

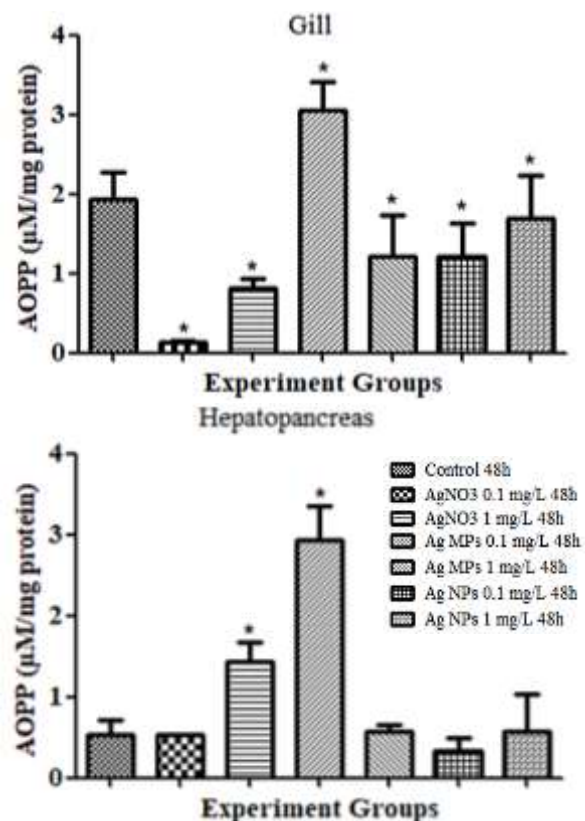


Fig. 2: The AOPP values of the gill and hepatopancreas tissues of narrow-clawed freshwater crayfish from silver derivatives exposure group and control group. The bars represented the mean \pm SE * indicate $P < 0.05$.

there was a significant decrease in gill and hepatopancreas tissue glutathione levels towards the control groups ($P < 0.05$). An increase in tissue glutathione level occurred due to the increase in concentration. As a result of 48-hour exposure to 1mg/L AgMPs and 0.1mg/L AgNPs in narrow-clawed freshwater crayfish, there was a significant decrease in tissue glutathione level compared to the control group ($P < 0.05$) (Fig. 3).

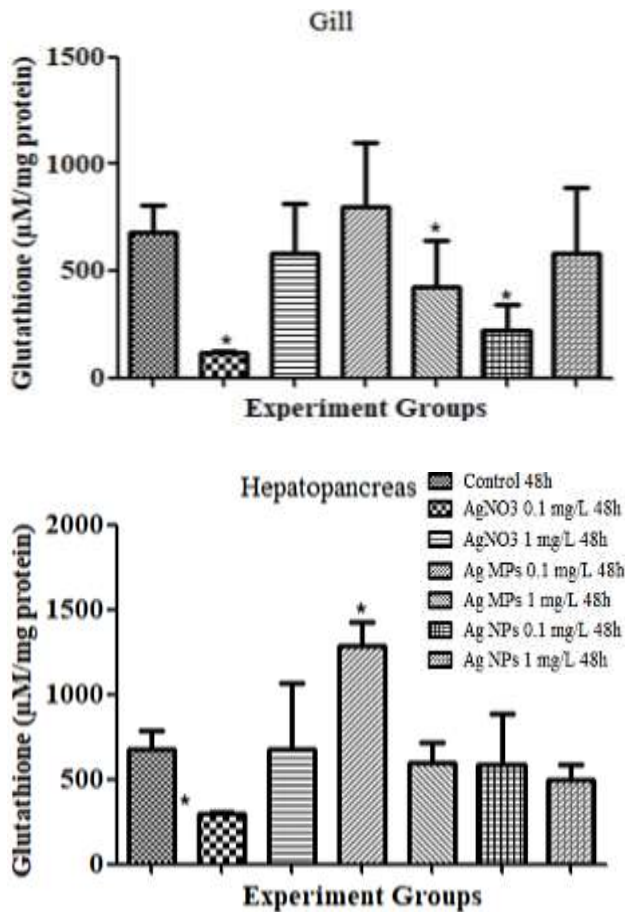


Fig. 3: The GSH values of the gill and hepatopancreas tissues of narrow-clawed freshwater crayfish from silver derivatives exposure group and control group. The bars represented the mean±SE * indicate $P < 0.05$.

Malondialdehydes: As a result of exposure of narrow-clawed freshwater crayfish to $AgNO_3$ for 48h, a significant increase occurred in the malondialdehyde level in the gill tissue due to the increase in concentration ($P < 0.05$). A significant increase in hepatopancreas tissue was observed only in the group applied 0.1mg/L $AgNO_3$ ($P < 0.05$). While there was a decrease in the gill tissues of crayfish exposed

to silver particles as a result of 0.1mg/L AgMPs exposure, an increase occurred as a result of AgNPs exposure (Fig. 4).

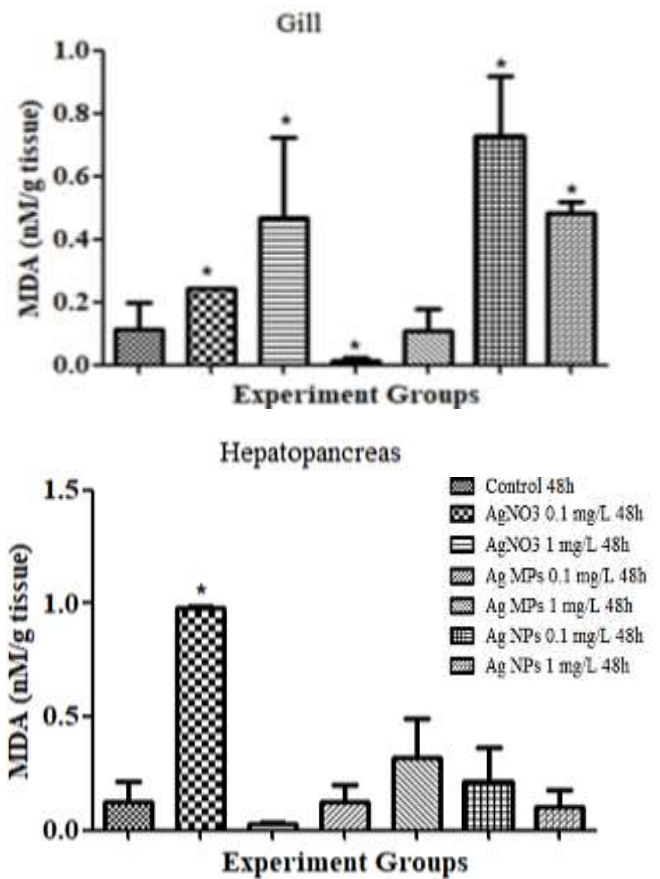


Fig. 4: The MDA values of the gill and hepatopancreas tissues of narrow-clawed freshwater crayfish from silver derivatives exposure group and control group. The bars represented the mean±SE * indicate $P < 0.05$.

Histopathology: Following 48-hour sublethal exposure to AgNPs, AgMPs and $AgNO_3$, antennal gland, muscular, gonadal, cardiac, and gastrointestinal tissues exhibited no significant histopathological alterations relative to control specimens. However, significant histoarchitectural modifications were identified in gill and hepatopancreatic tissues (Table 2). Gill epithelia displayed dose-dependent pathological manifestations, including hyperplasia, lamellar deformation, and hemocytic infiltration across silver particle size variants (Fig. 5). Hepatopancreatic analyses revealed tubular epithelial degeneration, stromal degeneration, and tubular atrophy, indicative of compromised excretory and metabolic functions (Fig. 6).

Table 2: Histopathological findings of the crayfish after 48 h exposure to sublethal concentrations of nanoparticles, microparticles and $AgNO_3$

Tissue/ Histopathology	Control	Nanoparticles Ag		Microparticles Ag		$AgNO_3$	
		0.1mg/L	1mg/L	0.1mg/L	1mg/L	0.1mg/L	1mg/L
Gill	* - - -	-	+	+	+	+	++
-Haemocytic infiltration in the veins	- - - -	++	+	++	+	++	++
-Lamellar deformations	- - - -	-	+	+	++	++	++
-Epithelial hyperplasia of lamellar epithelium	- - - -	++	+	+	++	+++	+++
Hepatopancreas	- - - -	+	-	+	-	+	+
-Tubule dystrophies (degeneration of tubule lumen, enlargement of tubules)	- - - -	+	+	+	+	+	++
--Interstitial tissue degeneration	- - - -	+	+	+	+	+	++
- Tubuler loss	- - - -	+	+	+	+	+	++

*(-) none (no histological alterations), which representing normal histological structure; (+) mild; (++) moderate and (+++) severe histopathological alterations in the tissues.

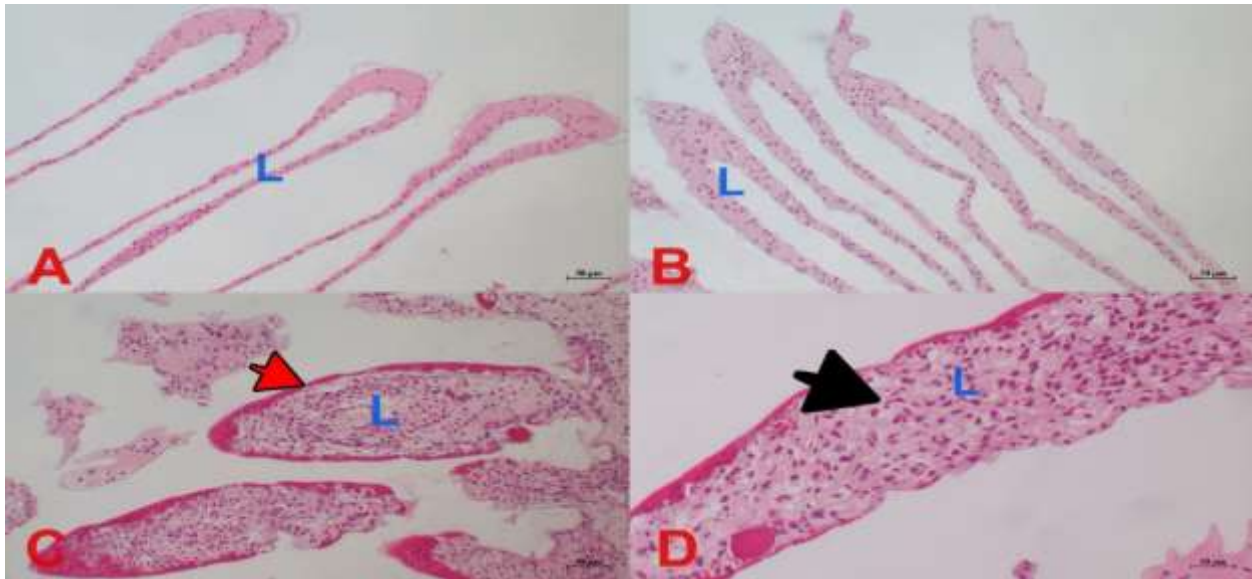


Fig. 5: Histologic appearance of gill tissues of crayfish (A) control: (B) following exposure to different particle size of AgNO₃ exhibited lamellar deformations (C) hemocytic infiltration (red arrow) (D) epithelial hyperplasia (black arrow) L: lamella.

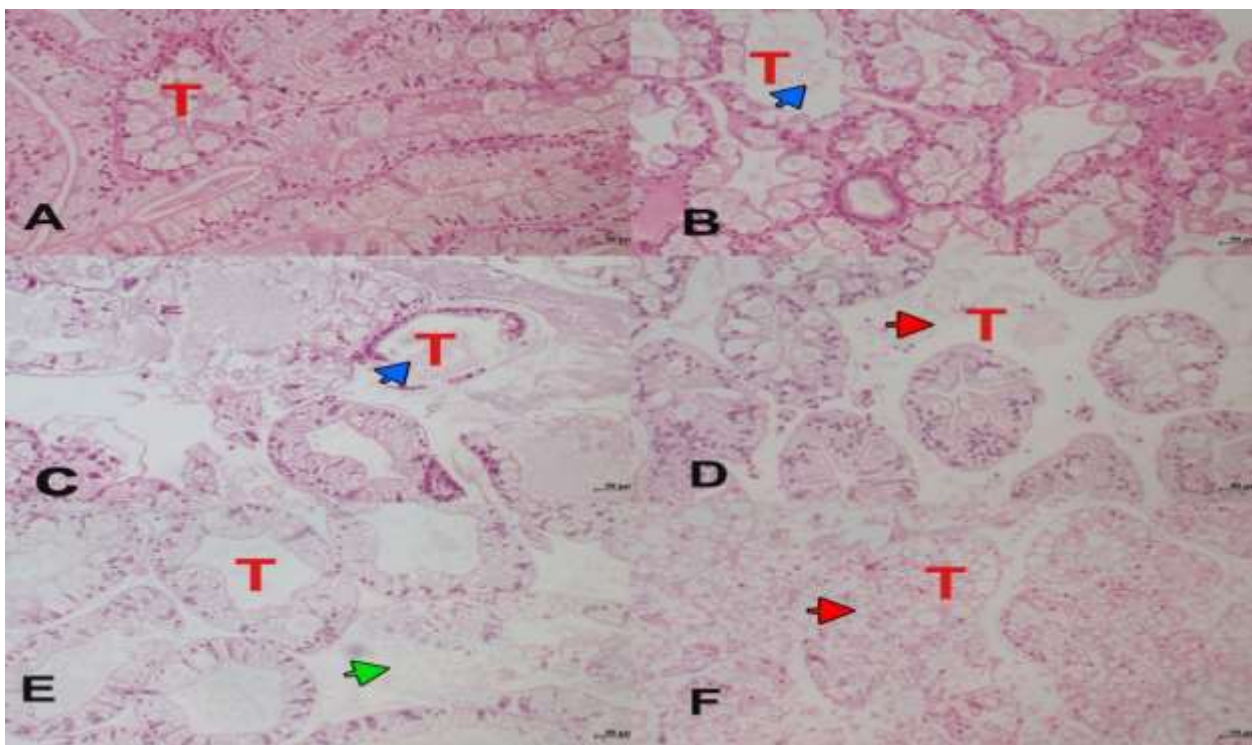


Fig. 6: Histologic appearance of hepatopancreas tissues of crayfish (A) control: (B) following exposure to different particle size of AgNO₃ tubular deformations (blue arrow) (C) tubular damage (blue arrow) (D) interstitial deformation (red arrow) (E) tubule loss (green arrow) (F) tubular damage (red arrow) T: tubule.

DISCUSSION

Silver is used as an antibacterial, antiviral, and antifungal agent in medical applications as well as personal care products. With the versatility of its usage area and the development of technology, silver has been processed and used in different particle sizes (Schluesener and Schluesener, 2013). As a result of their widespread use, silver and silver particles have become one of the sources of pollution in aquatic and terrestrial ecosystems. Apart from being used in medical and personal care products, they also contribute greatly to environmental pollution because they can be used

in different areas such as textiles and construction (Azadikhah *et al.*, 2023). In this study, narrow-clawed freshwater crayfish was used to evaluate the toxicological effects of AgNO₃, AgMPs, AgNPs on total hemocyte count, advanced oxidation protein products, tissue glutathione level, malondialdehyde and tissue histology.

The narrow-clawed freshwater crayfish were exposed to AgNO₃, AgMPs, AgNPs at concentrations of 0.1 and 1mg/L for 48 hours. There was a significant decrease in the total number of hemocytes in the AgNO₃ applied groups at 48 hours of exposure. There were changes in gill and hepatopancreas tissue biochemistry parameters depending

on the type of substance applied compared to the control groups. For this reason, silver and particle silver substances constitute a group of toxic substances that need to be investigated for aquatic organisms.

The total hemocyte count of aquatic invertebrates is a parameter that ensure informatory about the health status of the organism and its stress against environmental conditions. Changes in THC levels resulting from a weakened immune system due to the presence of a toxic substance in the aquatic environment may cause a decrease in the immune response of the organism or in cell mitotic activity (Günel *et al.* 2018; Arslan and Günel, 2023; Gao *et al.*, 2023). In a study investigating the effects of different toxic substances on THC levels of aquatic invertebrates, Berthod *et al.* (2021) found that there were changes in the THC levels of American Lobster (*Homarus americanus*) as a result of exposure to diesel and diluted bitumen substances. Günel *et al.* (2021) showed that *Astacus leptodactylus* treated with permethrin caused an increase in THC levels. Gao *et al.* (2023) showed that *Mytilus coruscus* exposed to microfibers and PCBs decreased THC levels. In this study, the increase or decrease in THC levels compared to control groups is consistent with the previous literature.

Gills are vital organ responsible for respiration for aquatic organisms (Andreyeva *et al.*, 2021). Gill tissue biochemistry and histopathological examinations are two of the methods used to evaluate the effects of toxic substances on the aquatic ecosystem (Hossain *et al.*, 2023). Increased concentrations of toxic aquatic ecosystem pollutants such as pesticides, metals, microparticles, and nanoparticles cause the formation of reactive oxygen species in tissue cells and affect tissue biochemistry by inhibiting metabolic processes (Joshy *et al.*, 2022; Hossain *et al.*, 2023). It has been shown that the tissue glutathione level in the gill tissues of *Cyprinus carpio* is lower in those exposed to different ZnO particles than in those exposed to ZnNPs, while the tissue level is higher in those exposed to ZnNPs (Hao *et al.*, 2013). This study supports findings in the literature and demonstrates the effects of different concentrations and particles of different sizes on gill tissue biochemistry and histology in aquatic organisms.

The hepatopancreas is an organ responsible for immune functions in aquatic crustacean invertebrates. Hepatopancreas cells produce immune molecules such as lectin, hemocyanin, and proteolytic enzymes. They activate the immune system as a result of exposure to biological, physical, or chemical factors (Röszer, 2014). It has been observed that permethrin exposure increases the MDA level in the *A. leptodactylus* hepatopancreas depending on the increase in exposure time (Günel *et al.*, 2021). A significant increase in MDA levels was observed in the hepatopancreas of *A. leptodactylus* following exposure to microplastics and zinc oxide nanoparticles (Banaee *et al.*, 2025). A shrimp *Caridina frossarum* exposed to iron oxide nanoparticles resulted an increase in MDA levels (Shahryari *et al.*, 2025). Zhang *et al.* (2022) observed that exposure of *Procambarus clarkii* to increasing Hg concentrations resulted in an increase in hepatopancreatic MDA levels. Hao *et al.* (2023) showed that the tissue glutathione level in carp liver exposed to different ZnO particles was higher in those exposed to nanoparticles, while the tissue MDA level was lower in those exposed to nanoparticles. In this study, it was observed that low dose AgNO₃ application significantly increased the

hepatopancreatic MDA level, which resulted in polyunsaturated fatty acid peroxidation in cell membranes. Therefore, the results of the present study support other studies.

In the present study, exposure to AgNO₃ resulted with some histological deformations in the gill and the hepatopancreas tissues. Epithelial hyperplasia, deformations and hemocytic infiltration were noticed in gill tissues of crayfish in pursuit of exposure to AgNO₃. Similarly, Brittle *et al.* (2012) reported histopathological changes in crayfish gill tissues such as clubbing, loss of pillar cells, and hyperplasia after exposure to 0.107, 0.160 and 0.214mg/L AgNO₃ concentrations. Desouky *et al.* (2013) observed hemocyte infiltration and swelling in the gill lamella tissue of *Procambarus clarkii* after 24 h exposure to 0.36mg/L ethion.

In this study, hepatopancreatic tissues of crayfish exposed to AgNO₃ exhibited necrosis within the tubules, along with tubular degeneration, interstitial tissue damage, and loss of tubular structure. To date, no published studies have specifically addressed the histological effects of AgNO₃ on crayfish gills. However, similar pathological features have been reported in response to other toxicants. For example, Zhang *et al.* (2019) observed tubular lumen degeneration in *Procambarus clarkii* following exposure to cadmium for 24, 48, and 72 hours. Chabera *et al.* (2021) reported marked tubular dilation, increased fibrillar cells, and hemocyte infiltration in the interstitial tissue of *Pacifastacus leniusculus* exposed to 2.7µg/L chloridazone over 30 days. Similarly, Li *et al.* (2023) identified epithelial vacuolization and tubular lumen dilation in hepatopancreas tissue after 72-hour exposure to lead (1, 10, and 50mg/L).

Conclusions: Based on the assumption that silver material in different sizes may cause toxic effects on aquatic organisms due to pollution in aquatic ecosystems, in this study, the determination of total hemocyte number and tissue biochemistry (AOPP, total glutathione and MDA) parameters; biomarkers of histological changes in gill and hepatopancreas tissues were used. Based on the results of the study, it was determined that silver in different sizes may have toxic effects on aquatic organisms, so caution should be exercised in its use.

Authors contribution: I. Simsek: wrote the paper, made analysis; P. Arslan Yüce: conceptualism, made the analyses, wrote the paper; G. Gul made the analyses; A.Ç. Günel conceptualism, supervision, made the analyses; Ö. Kuzukıran: wrote the paper; A. Filazi: revision; all the authors read and approved the article.

Data availability: The authors declare that all findings of this study are presented in the article.

Declarations

Competing interest: The authors declare that there is no conflict of interest.

Funding: There is no organization supporting the work.

Compliance with ethical standards: This article does not require informed consent.

Ethical approval: This article has not been conducted in any way requiring ethical approval.

REFERENCES

- Ale A, Liberatori G, Vannuccini ML, et al., 2019. Exposure to a nanosilver-enabled consumer product results in similar accumulation and toxicity of silver nanoparticles in the marine mussel *Mytilus galloprovincialis*. *Aqua Toxicol* 211:46–56.
- Andreyeva AY, Gostyukhina OL, Kladchenko ES, et al., 2021. Acute hypoxic exposure: effect on hemocyte functional parameters and antioxidant potential in gills of the pacific oyster, *Crassostrea gigas*. *Mar Environ Res* 169:105389.
- Arslan P and Günel A C. 2023. Does fipronil affect on aquatic organisms? Physiological, Biochemical, and Histopathological Alterations of Non-Target Freshwater Mussel Species. *Water* 15:334.
- Auclair J, Peyrot J, Wilkinson KJ, et al., 2021. The geometry of the toxicity of silver nanoparticles to freshwater mussels. *Comp Bio Physio Part C Toxicol Pharm* 239:108841.
- Azadikhah D, Yalsuyi AM, Saha S, et al., 2023. Biochemical and pathophysiological responses in *Capoeta capoeta* under lethal and Sub-Lethal exposures of silver nanoparticles. *Water* 15:585.
- Banaee M, Akhlaghi M, Soltanian S, et al., 2019. Acute exposure to chlorpyrifos and glyphosate induces changes in hemolymph biochemical parameters in the crayfish, *Astacus leptodactylus* (Eschscholtz, 1823). *Comp Bio Physio Part C Toxicol Pharm* 222:145–55.
- Banaee M, Zeidi A, Gholamhosseini A, et al., 2025. Potential synergistic effects of microplastics and zinc oxidenanoparticles: biochemical and physiological analysis on *Astacusleptodactylus*. *Ecotoxicology*, 34:769-78.
- Benli AÇK, 2014. The influence of etofenprox on narrow clawed Crayfish (*Astacus leptodactylus* Eschscholtz, 1823): Acute toxicity and sublethal effects on histology, hemolymph parameters, and total hemocyte counts. *Environ Toxicol* 30:887-94.
- Benli ACK, Köksal B and Özkul A. 2008. Sublethal ammonia exposure of Nile tilapia (*Oreochromis niloticus* L.): Effects on gill, liver and kidney histology. *Chemosphere* 72:1355-58.
- Berthod C, Bénard-Déraspe MH, Laplante IF, et al., 2021. Hemocyte health status based on four biomarkers to assess recovery capacity in american lobster (*Homarus americanus*) after exposure to marine diesel and diluted bitumen. *J Mar Sci Eng* 9:370.
- Bradford MM, 1976. A rapid and sensitive method for the quantitation of microgram quantities of protein utilizing the principle of protein-dye binding. *Anal Bioch* 72:248-54.
- Brittle S, Quach C, Baez M, et al., 2012. Histopathological changes in freshwater crayfish exposed to silver nanoparticles conference: american association for the advancement of science 2012 Annual Meeting Abstract Poter No 7415.
- Calisi A, Lorusso C, Gallego-Urrea JA, et al., 2022. Ecotoxicological effects of silver nanoparticles in marine mussels. *Sci Total Env* 851:158113.
- Chabera J, Stara A, Kubec J, et al., 2021. The effect of chronic exposure to chloridazon and its degradation product chloridazon-desphenyl on signal crayfish *Pacifastacus leniusculus*. *Ecotoxicol Environ Safe* 208:111645.
- Cote C, Lemarchand K, Desbiens I, et al., 2014. Immunotoxicity of silver nanoparticles in blue mussel (*Mytilus edulis*). *J Xenobiotics* 4:4896.
- Desouky MMA, Abdel-Gawad H and Hegazi B, 2013. Distribution, fate and histopathological effects of ethion insecticide on selected organs of the crayfish, *Procambarus clarkii*. *Food Chem Toxicol* 52:42-52.
- Dirican S, 2025. Comparison of heavy metal accumulation levels in abdominal muscles of Crayfish (*Astacus leptodactylus* Esch., 1823) from Kılıçkaya Reservoir, Sivas, Turkey. *Pol J Environ Stud* 34:1-8.
- Ellman GL, 1959. Tissue sulfhydryl groups. *Arch Biochem Biophys* 82:70-77.
- Ferdous Z and Nemmar A, 2020. Health impact of silver nanoparticles: a review of the biodistribution and toxicity following various routes of exposure. *Int J Mol Sci* 21:2375.
- Golokhvast K, Vitkina T, Gvozdenko T, et al., 2015. Impact of atmospheric microparticles on the development of oxidative stress in healthy City/Industrial seaport residents. *Oxidative Med Cell* 2015:412173.
- Gao Y, Huang W, liang N, et al., 2023. Combined effects of microfibers and polychlorinated biphenyls on the immune function of hemocytes in the mussel *Mytilus coruscus*. *Mar Environ Res* 192: 106214.
- Gomes T, Pereira CG, Cardosa C, et al., 2014. Effects of silver nanoparticles exposure in the mussel *Mytilus galloprovincialis*. *Mar Environ Res* 101:208-14.
- Günel AC, Katalay S, Erkmén B, et al., 2018. Antifouling bakır pritiyonun midye (*Mytilus galloprovincialis*)’de toplam hemosit sayıları üzerine etkilerinin belirlenmesi. *Ege J Fish Aqua Sci* 35:15-17.
- Günel AC, Tunca SK, Arslan P. et al. 2021. How does sublethal permethrin effect non-target aquatic organisms? *Environ Sci Pollut Res* 28:52405–417.
- Joshi A, Sharma SK, Mini KG, et al., 2022. Histopathological evaluation of bivalves from the southwest coast of India as an indicator of environmental quality. *Aquat Toxicol* 243:106076.
- Hao L, Chen L, Hao J, et al., 2013. Bioaccumulation and sub-acute toxicity of zinc oxide nanoparticles in juvenile carp (*Cyprinus carpio*): a comparative study with its bulk counterparts. *Ecotoxicol Environ Saf* 91:52-60.
- Harlioğlu MM, 2004. The present situation of freshwater crayfish, *Astacus leptodactylus* (Eschscholtz, 1823) in Turkey. *Aquaculture* 230:181-87.
- Hossain MA, Sarker TR, Sutradhar L, et al., 2023. Toxic effects of chlorpyrifos on the growth, hemocytes counts, and vital organ’s histopathology of freshwater mussel, *Lamellidens marginalis*. *J King Saud Univ Sci* 35(2):102482.
- Li Y, Zhou X, Guo W, et al., 2023. Effects of lead contamination on histology, antioxidant and intestinal microbiota responses in freshwater crayfish, *Procambarus clarkii*. *Aquat Toxicol* 265:106768.
- Li J, Mubashar M, Zulekha R, et al., 2025. Applications of coagulation-sedimentation and ultrafiltration for the removal of nanoparticles from water. *Sep Purifi Technol* 357:129920.
- Mihara M and Uchiyama M, 1978. Determination of malonaldehyde precursor in tissues by thiobarbituric acid test. *Anal Biochem* 86:271-78.
- Pandiarajan J and Krishnan M, 2017. Properties, synthesis and toxicity of silver nanoparticles. *Environ Chem Lett* 15:387-97.
- Reilly K, Ellis LJA, Davoudi HH, et al., 2023. Daphnia as a model organism to probe biological responses to nanomaterials—from individual to population effects via adverse outcome pathways. *Front Toxicol* 5:1178482.
- Röszer T, 2014. The invertebrate midintestinal gland (“hepatopancreas”) is an evolutionary forerunner in the integration of immunity and metabolism. *Cell Tissue Res* 358:685-95.
- Sati A, Ranade TN, Mali SN, et al., 2025. Silver nanoparticles (agnps) as potential antiviral agents: synthesis, biophysical properties, safety, challenges and future directions—update review. *Molecules* 30:2004.
- Schluesener JK and Schluesener HJ, 2013. Nanosilver: application and novel aspects of toxicology. *Arch Toxicol*, 87:569-76.
- Shahyari H, Sourinejad I, Gholamhosseini A, et al., 2025. Sub-lethal toxicity effects of iron oxide nanoparticles (IONPs) on the biochemical, oxidative biomarkers, and metabolic profile in *Caridina fassarum*. *J Trace Elements Med Bio* 88:127613.
- Sharma S, Pal D, Sidhwani HK, et al., 2025. Nanoparticles toxicity in aquatic ecosystems: experimental evidence from species. *Intern J Environ Sci* 11:626-44.
- Struzynski W, Dabrowska-Bouta B, Grygorowicz T, et al., 2013. Markers of oxidative stress in hepatopancreas of crayfish (*Orconectes limosus*, Raf) experimentally exposed to nanosilver. *Environ Toxicol* 29:1283-91.
- Şimşek İ, Arslan P, Günel AÇ, et al., 2024. Acute and chronic effects of silver nanoparticles (AgNPs) on *Unio delicatus*. *BEU Fen Bilimleri Dergisi* 13:101-6.
- Tunca E, Ucuncu E, Ozkan AD, et al., 2013. Tissue distribution and correlation profiles of heavy-metal accumulation in the freshwater crayfish *Astacus leptodactylus*. *Arch Environ Contam Toxicol* 64:676-91.
- Uçkun M, 2022. Assessing the toxic effects of bisphenol A in consumed crayfish *Astacus leptodactylus* using multi biochemical markers. *Environ Sci Pollut Res* 29:25194-208.
- Witko-Sarsat V, Friedlander M, Capeillère-Blandin C, et al., 1996. Advanced oxidation protein products as a novel marker of oxidative stress in uremia. *Kidney Int* 49:1304-13.
- Yavuzcan HY and Benli ACK, 2004. Nitrite toxicity to crayfish, *Astacus leptodactylus*, the effects of sublethal nitrite exposure on hemolymph nitrite, total hemocyte counts, and hemolymph glucose. *Ecotoxicol Environ Safe* 59:370-75.
- Zarnescu O, Petrescu AM, Gaspar A, et al., 2017. Effect of sublethal nickel chloride exposure on crayfish, *Astacus leptodactylus* ovary: An Ultrastructural, Autometallographic, and Electrophoretic Analyses. *Microsc Microanal* 23:668-78.
- Zhai Y, Hunting ER, Wouters M, et al., 2016. Silver nanoparticles, ions, and shape governing soil microbial functional diversity: Nano Shapes Micro. *Front Microbiol* 7:1123.
- Zhang Y, Li Z, Kholodkevich S, et al., 2019. Cadmium-induced oxidative stress, histopathology, and transcriptome changes in the hepatopancreas of freshwater crayfish (*Procambarus clarkii*). *The Sci Total Environ* 666:944-55.