

SHORT COMMUNICATION

Effects of *In-ovo* Administration of L-arginine on the Histo-morphometry of Thigh Muscles, Meat Characteristics and Growth Performance in Japanese Quails (*Coturnix coturnix japonica*)

Zubair Luqman¹, Saima Masood², Hafiz Muhammad Ali¹, Tauseef -ur Rehman³, Muhammad Altaf⁴, Nasir Iqbal⁵, Rana Muhammad Bilal⁶, Salahud Din⁵, Naveed Hussain⁵ and Sadaf Aslam⁵

¹Department of Anatomy and Histology, Faculty of Veterinary and Animal Sciences, The Islamia University of Bahawalpur, 63100-Pakistan; ²Department of Anatomy & Histology, University of Veterinary and Animal Sciences, Lahore, Pakistan; ³Department of Parasitology, Faculty of Veterinary and Animal Sciences, The Islamia University of Bahawalpur, 63100- Pakistan; ⁴Department of Clinical Medicine and Surgery, Faculty of Veterinary and Animal Sciences, The Islamia University of Bahawalpur, 63100- Pakistan; ⁵Department of Veterinary Surgery and Pet Sciences, University of Veterinary and Animal Sciences, Lahore, Pakistan; ⁶Department of Animal Nutrition, Faculty of Veterinary and Animal Sciences, The Islamia University of Bahawalpur, 63100-Pakistan

*Corresponding author: drzubairvet@hotmail.com; zubair.luqman@iub.edu.pk

ARTICLE HISTORY (20-525)

Received: October 12, 2020
Revised: March 18, 2021
Accepted: March 23, 2021
Published online: April 15, 2021

Key words:

Diameter of muscle fiber
Growth Performance
In-ovo inoculation
L-arginine
Muscle fascicles diameter
Thigh muscles

ABSTRACT

A total of 480 day old embryonated eggs were equally divided into four groups and treated with *in-ovo* inoculation of L-arginine as 1, 2, 3% and compared with control. Each group contained 120 eggs. G-1st was injected with 1% arginine solution (1gm/100ml distilled water). G-2nd was injected with 2% arginine solution (2gm/100ml distilled water). G-3rd was injected with 3% arginine (3gm/100ml distilled water). G-4th was control group. Four birds per replicate (n=5) were selected for slaughtering and collection of samples done for histo-morphometry and meat parameters analysis. The results of histo-morphometry of thigh muscles have indicated the growth of muscles. Drip loss, cooking loss of muscles have indicated the water holding capacity of tissues while lightness and yellowness of meat expressed the meat quality characteristics like tenderness, colour and juiciness of meat. Hence, it was concluded that the addition of L-arginine has significant beneficial effects on the growth performance of birds, histo-morphometry of thigh muscles and improved the meat quality on injecting 3% L-arginine compared to 2%, 1% and control groups.

©2021 PVJ. All rights reserved

To Cite This Article: Luqman Z, Masood S, Ali HM, Rehman TU, Altaf M, Iqbal N, Bilal RM, Din S, Hussain N and Aslam S, 2021. Effects of *in-ovo* administration of L-arginine on the histo-morphometry of thigh muscles, meat characteristics and growth performance in Japanese quail. Pak Vet J, 41(3): 456-458. <http://dx.doi.org/10.29261/pakvetj/2021.037>

INTRODUCTION

Limiting availability of nutrients within the eggs hinders the rapid growth of fast-growing strains of commercial birds, which can cause the increase mortality of embryo, poor nutritional status and decrease in growth performance (Ebrahimi *et al.*, 2017). Arginine is the limiting amino acid and regulates various hormones of body and cell signaling molecule pathway of growth. Limiting amino acids significantly enhance the mucosa of gastrointestinal tract (GIT) and immune system of broilers from hatching to market weight (Carroll *et al.*, 2016). The *in-ovo* feeding may meet the requirement of a specific ingredient at a specific time during the incubation period.

The L- arginine is the potent stimulator of creatine, urea and nitric oxide. Moreover, after hatching the *in-ovo* feeding of L-arginine, B-hydroxy and B-methyl butyrate may enhance the digestive enzymes production and uptake of nutrients from digestive mucosa of the birds. The mammalian target of rapamycin complex-1 (mTORC1) plays a vital role in metabolic pathways for the cellular reactions (Foye *et al.*, 2007). *In-ovo* feeding has beneficial effect on the histo-morphometry of body muscles and organs (Luqman *et al.*, 2019). *In-ovo* inoculation of lysine amino acid showed beneficial effects on the histology of thigh muscles and cecal tonsils (Luqman *et al.*, 2020). The objectives of current study were to evaluate the effects of *in-ovo* L-arginine amino

acid feeding on the histo-morphometry of thigh muscles, quality of meat and growth performance in Japanese quails.

MATERIALS AND METHODS

A total of 480 fertile eggs of Japanese quails having almost similar weight and size obtained from a single flock of University of Veterinary & Animal Sciences, Lahore, Pakistan was used in this study. All these 480 eggs were divided into four treatment groups which were further randomly divided into 120 eggs per treatment group and each group having replicate (n=5) eggs /group. These treatment groups were assigned as G1, G2 and G3 injected an amount of 0.3 ml (1, 2, 3 gm arginine/100ml distilled water) respectively, while Group 4th was injected only with 0.3 ml sterile distilled water and served as control group. A 27-gauge needles were used for the injecting the solution in all the groups at the depth of 15mm into air cell of all the eggs. Pyodine solution was used for cleaning the injection site on the eggs as antiseptic. Disinfection of the injecting site is very critical to avoid the contamination (Luqman *et al.*, 2020). Egg driller was used for making the hole in the eggs. After injecting the solution all the eggs were sealed with hot liquid paraffin to avoid the contamination during incubation period and kept into incubator for hatching.

Incubation, rearing and sample collection of birds:

Four hundred eighty 480 eggs were kept in incubator for hatching and out of these 240 birds were hatched out with 50% hatchability in all the groups. All the chicks were weighed and divided into four groups (60 bird /group). Shed of birds are properly fumigated before shifting them and all the birds were reared for five weeks on same commercial diet. After the completion of 5th week, four birds per replicate were selected for slaughtering and samples of muscles were collected.

Histo-morphometry procedure for muscle fibers and fascicles diameter of thigh muscles: Thigh muscle samples were preserved in 10% formalin solution. Paraffin embedding technique used for tissue processing. Staining of tissues was done by Hematoxylin and Eosin (H&E). Morphometry of tissues was done by Pixel Pro software fitted with Bright field microscope (Labomed USA) at 10X & 40X.

Parameters of meat quality

Measurement of drip loss: Honikel's gravimetric drip loss was estimated by the method of Honikel 1998. Muscle samples were weighed initially, placed in a meshed pouch and suspended in special container which was equipped with lid to avoid evaporation, and left in refrigerator at 4-6°C for 24 hours. Muscle fiber direction of the samples was horizontal to gravity. After 24 hours samples were removed from refrigerator and weighed again. The percent difference in two weights was used for calculating water-holding capacity.

Measurement of muscle color: The muscle color was checked with Minolta meter.

Measurement of muscle cooking loss: The cooking loss was checked by cooking.

Statistical analysis: For Statistical analysis, SPSS (Version 20) was used. One way-ANOVA applied on data as mean±SEM. Group differences were compared by Tukey's test which were significant at P<0.05.

RESULTS AND DISCUSSION

Histology of thigh muscles and meat quality parameters are presented in Table 1, indicated that *in-ovo* feeding of 3% L-arginine has significant effects on bird histo-morphometry and morphology, which increased the growth performance and final weight of the birds as indicated by FCR ratio and feed efficiency in Table 2. Fig. 1 and 2 are showing the histo-morphometry of thigh muscles. We compared drip loss with the study of Berri 2008, which performed same experiment in broilers by administering lysine amino acids. Cooking loss associated with quality of meat compared the results with Zhai (2016). mTOR cell signaling pathways are activated by injecting the arginine in the developing embryo of human and pig which enhance the viability of embryo (Kong *et al.*, 2012). Injecting the amino acid like arginine influences growing embryo and improves the post-hatch growth and performance. It can also be concluded that weight loss during the transportation was due to stress; this can be overcome by the provision of arginine during embryonic development. Broiler farm economy index and broiler feed price ratio were best in those groups fed *in-ovo* (Nayak *et al.*, 2016).

Table 1: Histology of thigh muscles and meat quality parameters comparison of control and *in-ovo* injected groups with L-arginine in Japanese quails (*Coturnix coturnix japonica*)

Thigh Muscles	1% Arginine	2% Arginine	3% Arginine	Control	P- Value
Muscle Fascicle Diameter (um)	360.30±1.01c	371.20±0.87b	378.60±1.57a	355.40±1.46d	0.001
Diameter of Muscle Fiber (um)	35.90±0.64c	38.10±0.48b	42.90±0.43a	31.20±0.38d	0.001
Cooking Loss (gm)	0.16±0.005b	0.26±0.09b	0.64±0.09b	0.22±0.004b	0.003
Drip Loss (gm)	1.520±0.008ab	1.495±0.008b	1.495±0.006b	1.529±0.009a	0.000
Lightness of Meat	44.96±0.04b	44.58±0.02c	44.29±0.02d	45.97±0.05a	0.001
Yellowness of Meat	10.39±0.008b	10.22±0.012c	10.14±0.009d	10.47±0.011a	0.000

Groups G1, G2 and G3 injected an amount of 1, 2 3 gm arginine/100ml distilled water) and G4 was control group; a-d Within the same row, different superscripts indicate significantly different means (P<0.05) with ± SEM of four groups.

Table 2: Feed conversion ratio (FCR) and feed efficiency (FE) of control and *in-ovo* injected groups with L-arginine in Japanese quails (*Coturnix coturnix japonica*)

FCR ratio	1% Arginine	2% Arginine	3% Arginine	Control	P-Value
Average of 5 th week	2.46±0.01b	2.28±0.008c	1.86±0.07d	2.66±0.01a	0.000
Average of 5 th week	0.49±0.005c	0.53±0.005b	0.61±0.005a	0.42±0.007d	0.002

Groups G1, G2 and G3 injected an amount of 1, 2 3 gm arginine/100ml distilled water) and G4 was control group; a-d Within the same row, different superscripts indicate significantly different means (P<0.05) with ± SEM of four groups.

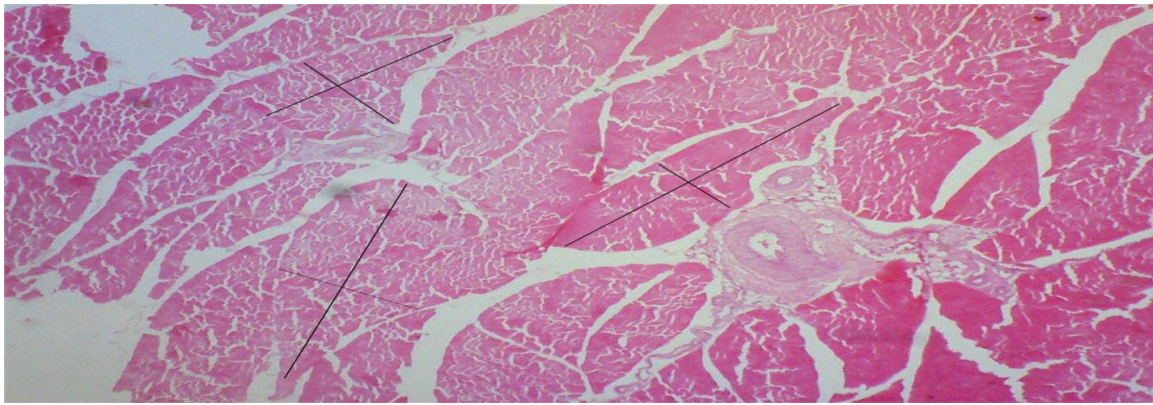


Fig. 1: Muscle fascicle diameter of thigh (um) in (*Coturnix coturnix japonica*).

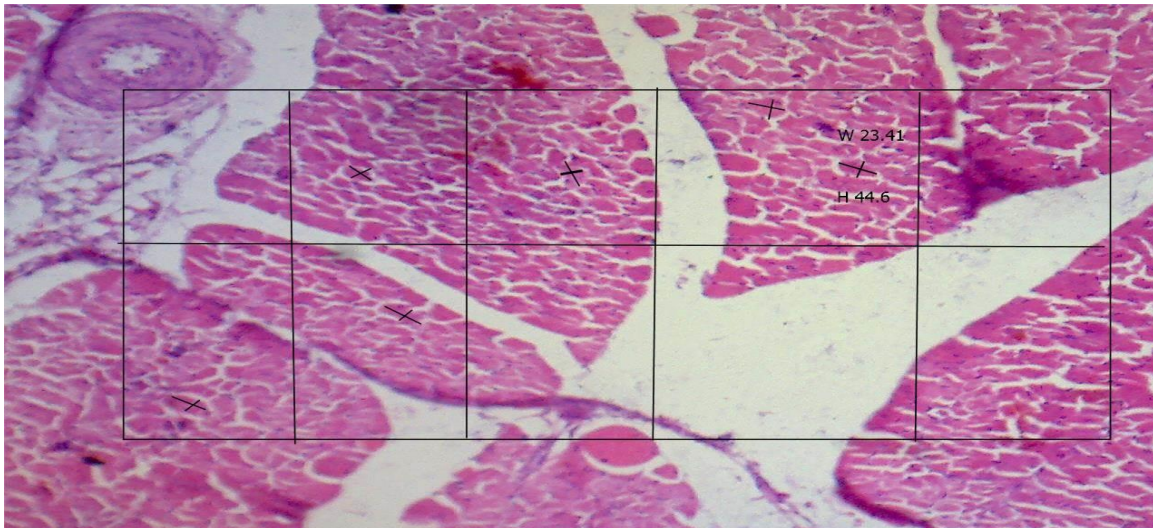


Fig. 2: Diameter of muscle fiber of thigh (um) in (*Coturnix coturnix japonica*).

Conclusions: This study concludes that 3% L-arginine *in-ovo* inoculation improved the growth performance, histo-morphometry of thigh muscles and quality of meat in Japanese quails as compared to their control group. This technique enhanced the pre- and post-hatchability development of muscles and energy requirements of quail birds. It has also great potential in poultry industry.

Acknowledgements: Experiment was performed in Avian Research and Training Center (ARTC) of Quail birds, University of Veterinary & Animal Sciences (UVAS), Lahore, Pakistan.

Author contributions: All the authors were involved in research, writing, critical revision, and final approval of this article.

REFERENCES

- Berri C, Besnard J and Relandeau C, 2008. Increasing dietary lysine increases final pH and decreases drip loss of broiler breast meat. *Poult Sci J* 87:480-4.
- Carroll B, Maetzel D and Maddocks OD, 2016. Control of TSC2-Rheb signaling axis by arginine regulates mTORC1 activity. *Elife* 5:e11058.
- Foye O, Ferket P and Uni Z, 2007. The effects of in ovo feeding arginine, β -hydroxy- β -methyl-butyrate, and protein on jejunal digestive and absorptive activity in embryonic and neonatal turkey poults. *Poult Sci J* 86:2343-9.
- Honikel KO, 1998. Reference methods for the assessment of physical characteristics of meat. *Meat Sci* 49:447-57.
- Kong X, Tan B and Yin Y, 2012. L-Arginine stimulates the mTOR signaling pathway and protein synthesis in porcine trophectoderm cells. *J Nutr Biochem* 23:1178-83.
- Luqman Z, Ali HM, Zahra N, et al., 2020. In-ovo effects of Lysine amino acid on the histo-morphometry of thigh muscles, cecal tonsils and pH in Japanese quail. *Pak Euro J Med Life Sci* 3:1-5.
- Luqman Z, Iqbal N, Ali HM, et al., 2020. Disinfection of corona virus in histopathology laboratories. *Clin Anat* pp: 1-2. <https://doi.org/10.1002/ca.23636>.
- Luqman Z, Masood S, Zaneb H, et al., 2019. Effect of in ovo inoculation on productive performances and histo-physiological traits in commercial birds. *Int J Sci Engineer Res* 10:1664-73.
- Nayak N, Rajini RA, Ezhilvalavan S, et al., 2016. Influence of In-ovo Arginine Feeding on Post-hatch Growth Performance and Economics of Broilers. *J Anim Res* 6:585.
- Zhai W, Schilling M and Jackson V, 2016. Effects of dietary lysine and methionine supplementation on Ross 708 male broilers from 21 to 42 days of age (II): breast meat quality. *J Appl Poult Res* 25:212-22.