



## RESEARCH ARTICLE

### Hepatoprotective Potential of Genkwanin Against Aflatoxin B<sub>1</sub>-Induced Biochemical, Inflammatory and Histopathological Toxicity in Rats

Muhammad Umar Ijaz<sup>1</sup>, Ayesha Ishtiaq<sup>1</sup>, Nazia Ehsan<sup>2</sup>, Muhammad Imran<sup>3</sup> and Guo-ping Zhu<sup>1\*</sup>

<sup>1</sup>Anhui Provincial Key Laboratory of Molecular Enzymology and Mechanism of Major Diseases, College of Life Sciences, Anhui Normal University, Wuhu, Anhui, China

<sup>2</sup>Department of Zoology, Wildlife and Fisheries, University of Agriculture, Faisalabad, Pakistan

<sup>3</sup>Department of Parasitology, University of Agriculture, Faisalabad, Pakistan

\*Corresponding author: gpz2012@ahnu.edu.cn

#### ARTICLE HISTORY (22-084)

Received: March 7, 2022  
Revised: June 6, 2022  
Accepted: June 13, 2022  
Published online: July 07, 2022

#### Key words:

Aflatoxins B<sub>1</sub>  
Aflatoxins  
Genkwanin  
Antioxidant enzymes  
Oxidative stress  
Hepatotoxicity

#### ABSTRACT

Aflatoxin B<sub>1</sub> (AFB<sub>1</sub>) is a potent mycotoxin in humans and animals. The exposure to AFB<sub>1</sub> is evidenced to implicate multi-organ toxicity in humans and animals, particularly hepatotoxicity. Genkwanin (GNK) is a bioactive non-glycosylated flavonoid with potential pharmacological properties. Therefore, the current study aimed to determine the dose-dependent role of GNK against AFB<sub>1</sub>-instigated hepatotoxicity. The investigation was carried out on 96 adult male albino rats, which were equally distributed into eight groups. The effect of 3 different doses of GNK (5, 10 and 20 mg/kg-1) was evaluated against the toxicity elicited by 50 µg/kg<sup>-1</sup> of AFB<sub>1</sub>. After the administration of AFB<sub>1</sub> and GNK by the oral gavage for 56 days, the biochemical and hepatic serum markers were determined in addition to histopathological observation. AFB<sub>1</sub> exposure disrupted the biochemical profile by declining the activities of antioxidant enzymes (catalase, superoxide dismutase, glutathione peroxidase, glutathione reductase and glutathione content), while elevating the concentration of reactive oxygen species and malondialdehyde level. Furthermore, AFB<sub>1</sub> exposure notably elevated the levels of hepatic serum enzymes (alkaline phosphatase, alanine aminotransferase and aspartate aminotransferase) along with the levels of inflammatory markers, nuclear factor kappa-B, tumor necrosis factor- $\alpha$ , Interleukin-6, Interleukin-1 $\beta$  and activity of cyclooxygenase-2. Besides, AFB<sub>1</sub> induction caused histopathological impairments in hepatic tissues. Nonetheless, GNK co-administration remarkably ameliorated all the damages of the hepatic system induced by AFB<sub>1</sub> administration to the rats. Therefore, it was demonstrated that the GNK could potentially cure AFB<sub>1</sub>-instigated hepatotoxicity attributing to its antioxidative and ant-inflammatory potential.

**To Cite This Article:** Ijaz MU, Ishtiaq A, Ehsan N, Imran M and Zhu G, 2022. Hepatoprotective potential of genkwanin against aflatoxin b<sub>1</sub>-induced biochemical, inflammatory and histopathological toxicity in rats. Pak Vet J, 42(4): 499-504. <http://dx.doi.org/10.29261/pakvetj/2022.048>

#### INTRODUCTION

Aflatoxins (AFs) are toxic fungal metabolites, predominantly present in *Aspergillus flavus* and *A. parasiticus*. Food and Drug Administration (FDA) regarded the aflatoxins as unavoidable contaminants, which affect a wide range of food commodities (Gell and Carbone, 2019). At present, more than 20 AFs are isolated and identified in which, aflatoxin B<sub>1</sub> (AFB<sub>1</sub>) is most toxic and evidenced to show highly immunotoxic, genotoxic, and nephrotoxic and hepatotoxic health effects (Marchese *et al.*, 2018; Ashraf *et al.*, 2021; Bhatti

*et al.*, 2021). Around the globe, 4.5 billion people suffer from AFB<sub>1</sub> intoxication, and around 25% of all high-dose acute exposure leads to death (Voth-Gaeddert *et al.*, 2018). The LD<sub>50</sub> of AFB<sub>1</sub> is noted to be 0.36 mg/kg<sup>-1</sup> (Nonaka *et al.*, 2009). However, 1.7 mg/kg<sup>-1</sup> of daily AF exposure is estimated in the countries having higher AFs generation and dietary contamination (Faridha *et al.*, 2006; Imran *et al.*, 2020). AFB<sub>1</sub> is particularly considered a hepatotoxin because of its tendency to implicate liver damages in living organisms. Furthermore, AFB<sub>1</sub> is listed as a human class I carcinogen by the International Agency for Cancer

Research as its exposure resulted in 4.6 to 28.2% of all hepatocellular carcinoma cases (Abrar *et al.*, 2013).

AFB<sub>1</sub> exposure to humans occurs through contaminated food, including cereals, tree nuts, oil seeds, spices, and other commodities (Haque *et al.*, 2020). After being taken up by the body, it releases into the blood circulation and gets transported to various organs, especially the liver (Li *et al.*, 2019). Liver is the primary target organ and biotransformation point that gets affected by the toxic effects of AFB<sub>1</sub> (Kamdem *et al.*, 2009). In the liver, AFB<sub>1</sub> converts into the more detrimental form, AFB<sub>1</sub> 8, 9 epoxide, with the aid of cytochrome (CYP) P450. The AFB<sub>1</sub> activation culminates in the weakening of antioxidant capacity of hepatocytes, which subsequently elevates the concentration of reactive oxygen species (ROS) and lays the foundation of oxidative damages, such as lipid peroxidation (LP), and disrupts the biomolecules (lipids, proteins, and DNA) in cellular systems (Jiang *et al.*, 2019). Hence, considering the harmful effects of AFB on the hepatic system of living organisms, research on finding the therapeutic treatment against AFB<sub>1</sub>-induced hepatotoxicity is necessary.

Flavonoids are used as the traditional Chinese medicine to counter the oxidative stress (OS) and organ toxicities by stabilizing the enzymatic levels (Ijaz *et al.*, 2022). Genkwanin (GNK; 5,4'-dihydroxy-7-methoxy flavone) is a bioactive non-glycosylated flavonoid, which was primarily isolated from *Daphne genkwa* in 1932 with reported immunomodulatory, anti-oxidative and anti-inflammatory activities (Gao *et al.*, 2014). Furthermore, GNK was referred as the favorable drug candidate as it fulfills the Lipinski's rule of five (Rakib *et al.*, 2020). Hence, depending upon the considerable bioactive properties of GNK, the current research was meant to assess the ameliorative potency of GNK against AFB<sub>1</sub>-instigated hepatotoxicity.

## MATERIALS AND METHODS

**Chemicals:** AFB<sub>1</sub> and GNK were bought from Sigma-Aldrich (Germany).

**Animals:** Adult male albino rats (*Rattus norvegicus*) weighing 200±20 g were kept in well-ventilated steel cages in the animal faculty at Agriculture University Faisalabad. They all were given standard chow and tap water (H<sub>2</sub>O) *ad libitum* and exposed to the photoperiod of 12h light/ 12h dark cycle and temperature (22-26°C). All protocols performed in the investigation were authorized by the ethical committee for the handling of animals under controlled conditions at Agriculture University Faisalabad.

**Experimental Protocol:** 96 sexually mature healthy male albino rats (*Rattus norvegicus*) were divided into 8 groups containing 12 rats in each group. They were acclimatized to the laboratory conditions for 1-week prior to the commencement of experiment and following treatments were given to them by oral gavage:

Group I: Control rats will be administered with the corn oil with 1% DMSO.

Group II: AFB<sub>1</sub>-induced group will be orally provided with the 50 ug/kg of AFB<sub>1</sub>.

Group III, IV and V: Co-treated groups (AFB<sub>1</sub> + GNK1, AFB<sub>1</sub> + GNK2 and AFB<sub>1</sub> + GNK3) will be provided with the AFB<sub>1</sub> as well as the various doses of GNK to assess the dose-dependent effect of GNK against the AFB<sub>1</sub>-instigated liver toxicity. Apart from the provision of 50 ug/kg of AFB<sub>1</sub>, 5, 10 and 20 mgkg<sup>-1</sup> of GNK will be administered to the low, medium and high dose' GNK-induced groups respectively.

Group VI, VII and VIII: 5, 10 and 20 mgkg<sup>-1</sup> of GNK will be provided to the low, medium and high dose' GNK-treated groups respectively.

The entire experiment was conducted for 56 days. The 5, 10 and 20 mgkg<sup>-1</sup> of GNK were chosen according to the study of Bao *et al.* (2019). At the end of experimentation, rats were killed, blood was collected in tubes and liver was removed. Serum was separated by centrifugation of blood at 3000xg for 10 min and kept at -20°C until further assessments. Half part of liver was kept at -80°C, washed with chilled saline and later on homogenate was prepared by mincing the liver tissue to obtain the supernatant. Other half of liver was kept for histoarchitectural observation after fixing in 10% formaldehyde.

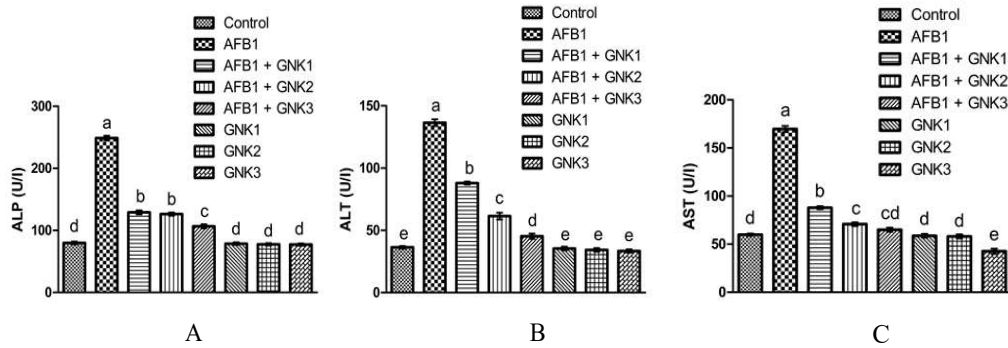
**Biochemical Assay:** The activity of catalase (CAT) was estimated by the technique of Aebi (1974). The superoxide dismutase (SOD) activity was computed via the methodology reported by Kakkar *et al.* (1984). The glutathione peroxidase (GPx) activity was assessed via the method of Rotruck *et al.* (1973). The glutathione reductase (GSR) activity was evaluated via the protocol of Carlberg and Mannervik (1975), while glutathione (GSH) content was assessed via the methodology of Jollow *et al.* (1974). The concentration of ROS was ascertained by the technique of Hayashi *et al.* (2007). The level of malondialdehyde (MDA) was quantified according to the procedure of Ohkawa *et al.* (1979).

**Hepatic serum enzymes:** Hepatic serum levels of ALP, ALT and AST were measured in accordance with the ELISA kits (Abcam, MA, USA) bought from AMP diagnostics.

**Inflammatory markers:** The levels of NF-κB, TNF-α, IL-1β and IL-6, and COX-2 activity were ascertained with ELISA kit (Cusabio Technology Llc, Houston, TX, USA) as per the manufacturer's guidance.

**Histopathology of hepatic tissues:** Firstly, hepatic tissues were washed gently in 0.9% chilled saline, kept in 10 % formaldehyde solution for one day. Secondly, dehydrated in ascending grades of alcohol and encased in paraffin wax. In the next step, sequentially paraffin-embedded slices (5-μm) were cut via microtome and stained with hematoxylin-eosin (H & E). In the last step, slides were analyzed under Leica microscope at 400X.

**Statistical analysis:** The result values were shown as the Mean±SEM. One-way ANOVA followed by Tukey's multiple comparison test was applied to interpret the entire data using Minitab. P<0.05 was considered statistically significant.



**Fig. 1:** Effect of AFB<sub>1</sub> and various doses of GNK on the activities of A) ALP, B) ALT, and C) AST. All bars represent Mean±SEM values (n = 12 rats/group). Bars represent mean±SEM values (n=96). Unlike superscripts indicate significant differences among groups (P<0.05).

**Table 1:** Estimation of biochemical markers in various groups.

Parameters	GROUPS							
	Control	AFB <sub>1</sub>	AFB <sub>1</sub> + GNK1	AFB <sub>1</sub> + GNK2	AFB <sub>1</sub> + GNK3	GNK1	GNK2	GNK3
CAT (Umg <sup>-1</sup> protein)	10.33±0.28 <sup>a</sup>	4.51±0.21 <sup>d</sup>	5.89±0.19 <sup>cd</sup>	6.92±0.28 <sup>bc</sup>	8.15±0.27 <sup>b</sup>	10.52±0.50 <sup>a</sup>	10.67±0.62 <sup>a</sup>	10.97±0.50 <sup>a</sup>
SOD (Umg <sup>-1</sup> protein)	8.67±0.35 <sup>ab</sup>	4.08±0.29 <sup>d</sup>	5.06±0.24 <sup>cd</sup>	5.83±0.33 <sup>cd</sup>	6.88±0.34 <sup>bc</sup>	8.81±0.60 <sup>ab</sup>	8.99±0.71 <sup>a</sup>	9.02±0.60 <sup>a</sup>
GPx (Umg <sup>-1</sup> protein)	19.47±0.99 <sup>a</sup>	10.31±0.54 <sup>c</sup>	12.58±0.60 <sup>bc</sup>	14.77±0.64 <sup>b</sup>	18.70±0.70 <sup>a</sup>	19.62±0.79 <sup>a</sup>	19.9±0.86 <sup>a</sup>	20.22±0.69 <sup>a</sup>
GSR (nM NADPH oxidized/min/mg tissue)	6.94±0.25 <sup>ab</sup>	3.08±0.27 <sup>c</sup>	5.15±0.42 <sup>b</sup>	5.93±0.48 <sup>ab</sup>	6.35±0.39 <sup>ab</sup>	6.99±0.55 <sup>a</sup>	7.11±0.50 <sup>a</sup>	7.23±0.37 <sup>a</sup>
GSH (nM/min/mg protein)	11.76±0.41 <sup>a</sup>	3.85±0.28 <sup>c</sup>	7.17±0.35 <sup>b</sup>	7.61±0.34 <sup>b</sup>	8.51±0.34 <sup>b</sup>	11.95±0.39 <sup>a</sup>	11.82±0.37 <sup>a</sup>	12.14±0.44 <sup>a</sup>
ROS (Umg <sup>-1</sup> tissue)	1.38±0.08 <sup>d</sup>	9.11±0.34 <sup>a</sup>	3.46±0.25 <sup>c</sup>	5.19±0.39 <sup>b</sup>	4.86±0.48 <sup>b</sup>	1.34±0.08 <sup>d</sup>	1.26±0.07 <sup>d</sup>	1.28±0.09 <sup>d</sup>
MDA (nmol/mg protein)	0.66±0.06 <sup>d</sup>	2.05±0.11 <sup>a</sup>	1.67±0.04 <sup>b</sup>	1.56±0.06 <sup>b</sup>	1.15±0.06 <sup>c</sup>	0.62±0.03 <sup>d</sup>	0.59±0.03 <sup>d</sup>	0.41±0.04 <sup>d</sup>

Results represent mean±SEM values (n = 12). Unlike superscripts indicate significant differences among groups (P < 0.05).

**Table 2:** Estimation of inflammatory markers in various groups

Parameters	GROUPS							
	Control	AFB <sub>1</sub>	AFB <sub>1</sub> + GNK1	AFB <sub>1</sub> + GNK2	AFB <sub>1</sub> + GNK3	GNK1	GNK2	GNK3
NF-κB (ngg <sup>-1</sup> tissue)	18.72±0.69 <sup>e</sup>	79.40±0.85 <sup>a</sup>	36.30±0.54 <sup>b</sup>	29.26±0.52 <sup>c</sup>	24.66±0.74 <sup>d</sup>	18.60±0.75 <sup>e</sup>	17.94±0.52 <sup>e</sup>	17.77±0.64 <sup>e</sup>
TNF-α (ngg <sup>-1</sup> tissue)	8.74±0.24 <sup>d</sup>	17.59±0.63 <sup>a</sup>	13.91±0.57 <sup>b</sup>	12.77±0.72 <sup>bc</sup>	11.39±0.63 <sup>c</sup>	8.63±0.28 <sup>d</sup>	8.26±0.28 <sup>d</sup>	7.73±0.30 <sup>d</sup>
IL-1β (ngg <sup>-1</sup> tissue)	24.44±0.46 <sup>d</sup>	74.83±0.82 <sup>a</sup>	34.36±0.53 <sup>b</sup>	32.46±0.71 <sup>b</sup>	29.25±0.80 <sup>c</sup>	24.18±0.76 <sup>d</sup>	23.24±0.67 <sup>d</sup>	22.61±0.82 <sup>d</sup>
IL-6 (ngg <sup>-1</sup> tissue)	8.49±0.28 <sup>d</sup>	19.69±0.53 <sup>a</sup>	14.28±0.80 <sup>b</sup>	13.14±0.77 <sup>bc</sup>	11.50±0.64 <sup>c</sup>	8.36±0.30 <sup>d</sup>	8.04±0.35 <sup>d</sup>	6.92±0.29 <sup>d</sup>
COX-2 (ngg <sup>-1</sup> tissue)	17.61±0.65 <sup>de</sup>	66.27±0.99 <sup>a</sup>	30.81±0.89 <sup>b</sup>	26.46±0.94 <sup>c</sup>	20.89±1.35 <sup>d</sup>	17.12±0.68 <sup>def</sup>	15.53±0.70 <sup>def</sup>	13.33±0.86 <sup>f</sup>

Results represent mean±SEM values (n = 12). Unlike superscripts indicate significant differences among groups (P < 0.05).

## RESULTS

**Impact of treatments on biochemical assay:** Table 1 displays the results of the biochemical assay. AFB<sub>1</sub> induction significantly (P<0.05) lowered the activities of CAT, SOD, GPx, GSR, and GSH content, while elevated the ROS concentration and level of MDA in the AFB<sub>1</sub> administered rats in contrast to the control rats. However, GNK co-administration with AFB<sub>1</sub> dose-dependently raised the activities of CAT, SOD, GPx, GSR, and GSH content, while substantially (P<0.05) lowered the ROS concentration and MDA level in comparison to the AFB<sub>1</sub>-administered group. Nevertheless, among all the co-treated groups, the highest increase in antioxidative enzymes was noticed in the AFB<sub>1</sub> + GNK3-induced group which was supplemented with the 20 mgkg<sup>-1</sup> of GNK. Additionally, the mean values of the only GNK treated and the control groups were quite close to each other.

### Impact of treatments on hepatic serum enzymes:

Figure 1 demonstrates the levels of hepatic serum enzymes. The present investigation revealed that AFB<sub>1</sub> intoxication significantly (P<0.05) elevated the serum levels of ALP, ALT and AST in the AFB<sub>1</sub>-induced group versus the control group. However, GNK brought a decline in the levels of ALP, ALT and AST in dose-

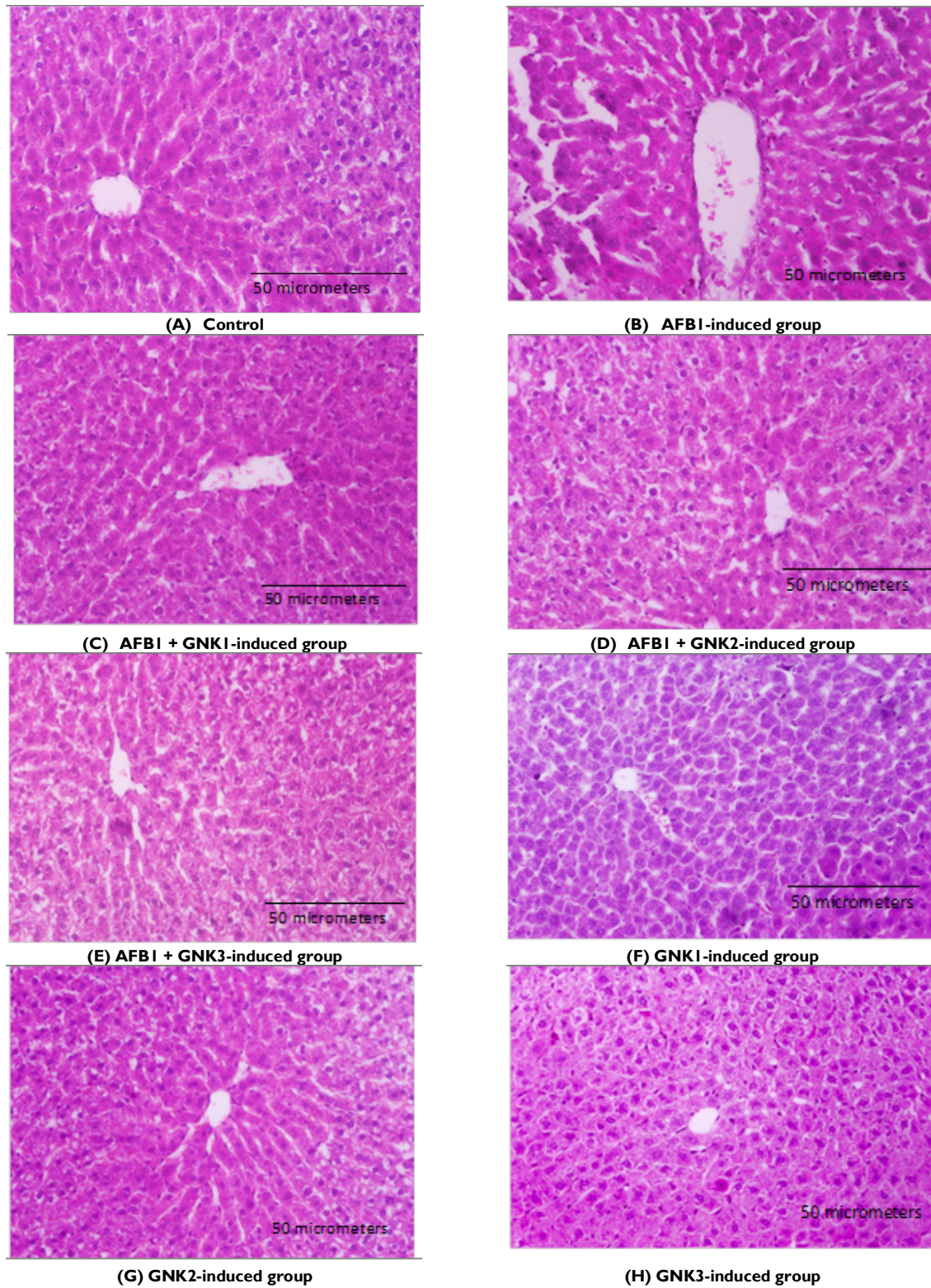
dependent manner in the cotreated group versus the AFB<sub>1</sub> group. However, the highest reduction was observed at the administration of high dose (20 mgkg<sup>-1</sup>) of GNK. Additionally, the only GNK treated groups presented insignificant differences in the levels of hepatic serum enzymes as contrasted with the control group.

**Impact of treatments on inflammatory markers:** Table 2 illustrates the relative changes in the values of inflammatory markers. AFB<sub>1</sub> exposure considerably (P<0.05) elevated the levels of NF-κB, TNF-α, IL-1β, IL-6, and COX-2 activity in the AFB<sub>1</sub>-intoxicated rats versus the control rats. However, co-administration of GNK at concentrations of 5, 10 and 20 mgkg<sup>-1</sup> declined the levels and activity of all the above-stated inflammatory markers versus the AFB<sub>1</sub> group. Nonetheless, the highest decline was noted in the co-treated group (AFB<sub>1</sub> + GNK3) with higher GNK dose. Furthermore, there was an insignificant difference between the only GNK treated (5, 10 and 20 mgkg<sup>-1</sup>) and the control groups.

**Impact of treatments on hepatic histopathology:** Figure 2 depicts the relative alterations in the histopathology of hepatic tissues. AFB<sub>1</sub> induction significantly (P<0.05) elevated the sinusoids dilation, central venule disruption, necrosis, and hepatic cells death in the AFB<sub>1</sub>-intoxicated group versus the control group. However, co-

administration of GNK with AFB<sub>1</sub> dose-dependently mitigated the intensity of histopathological damages such as central venule disruption, reduction in the dilation of sinusoids with no necrotic cells, and restored the standard

structure of hepatocytes in the co-administered groups versus the AFB<sub>1</sub> group as shown in Figure 2. However, structure of liver tissues of only GNK administered-rats was quite similar to the control rats.



**Fig. 2:** Ameliorative effect of GNK against AFB<sub>1</sub>-instigated histological damages in liver (Hematoxylin-Eosin, 400X). A) Control group; B) AFB<sub>1</sub>-administered rats (50 ugkg<sup>-1</sup>); C) AFB<sub>1</sub> + GNK1-induced rats (50 ugkg<sup>-1</sup> + 5 mgkg<sup>-1</sup>); D) AFB<sub>1</sub> + GNK2-induced rats (50 ugkg<sup>-1</sup> + 10 mgkg<sup>-1</sup>); E) AFB<sub>1</sub> + GNK3-induced rats (50 ugkg<sup>-1</sup> + 20 mgkg<sup>-1</sup>); F) GNK1-induced rats (5 mgkg<sup>-1</sup>); G) GNK2-induced rats (10 mgkg<sup>-1</sup>); H) GNK3-induced rats (20 mgkg<sup>-1</sup>).

## DISCUSSION

In the current investigation, biochemical analysis revealed that AFB<sub>1</sub>-intoxication potently reduced the activities of antioxidant enzymes such as CAT, SOD, GPx, GSR and GSH content; while raising the ROS concentration and levels of MDA. SOD is one of most vital antioxidant enzymes, which transforms superoxide anion (O<sub>2</sub><sup>-</sup>) into hydrogen peroxide (H<sub>2</sub>O<sub>2</sub>), while CAT is shown to convert H<sub>2</sub>O<sub>2</sub> into H<sub>2</sub>O. It also separates O<sub>2</sub><sup>-</sup> produced by NADPH oxidase from neutrophils (Nieskens *et al.*, 2018). GSH is regarded as a co-factor for GPx, which hinders the cells against OS by reducing the levels of H<sub>2</sub>O<sub>2</sub> as well as other peroxides. Furthermore, reduction in GSH functions as an electron donor in these reactions, whereas GSR maintains the level of GSH content (Ali *et al.*, 2020). Hence, a reduction in the activities of antioxidant enzymes boosts the ROS concentration. When the concentration of ROS overwhelms the body's antioxidant-defense capacity, OS occurs that subsequently destroys the selective permeability of the cell membrane, which results in LP that harms cells, tissues, and organs (Forman and Zhang, 2021). Nevertheless, the GNK co-administration remarkably diminished the ROS concentration and levels of MDA, presumably by augmenting the activities of antioxidative enzymes.

A phenomenal increase was seen in the levels of hepatic serum enzymes (ALP, ALT, and AST) after AFB<sub>1</sub> intoxication. As reported previously, these enzymes are present in hepatocytes, and serum levels are usually low. Nonetheless, when hepatocytes are injured, their membranes become more permeable or may even be damaged, letting their enzymes leak into the blood (Nagai *et al.*, 2016). Another recent investigation has also noted the rise in level of hepatic serum enzymes following the AFB<sub>1</sub> administration in rats (Owumi *et al.*, 2022). Furthermore, elevated levels of serum enzymes revealed that the OS was the main culprit behind damaged hepatocellular function (Knudsen *et al.*, 2016). However, administration of GNK to rats potentially lowered the levels of liver serum enzymes by reducing OS.

AFB<sub>1</sub> intoxication further led to a profound elevation in the levels of inflammatory markers such as NF-κB, TNF-α, IL-1β, IL-6 and COX-2 activity. NF-κB is one of the key inflammatory mediator that activates quickly after sensing the internal or external cellular stimulation that eventually raises the expression of TNF-α, IL-1β, IL-6 and COX-2 activity (Taniguchi and Karin, 2018). Hence, obstructing the nuclear translocation of inflammatory markers like NF-κB initiates a systematic cascade to inhibit inflammation. In the present research, co-administration of GNK potentially reduced the levels of inflammatory markers, which may be attributed to its ring structure (Gao *et al.*, 2014). In an earlier study, it was revealed that the anti-inflammatory role of flavones is due to the methoxylation of the 5- or 7-hydroxyl groups on the A-ring or non-methoxylation of the 3'-hydroxyl groups on the B-ring (During and Larondelle, 2013).

Histopathological analysis of hepatic tissues demonstrated that AFB<sub>1</sub> exposure caused severe disruption of the central venule, sinusoid dilation, and

necrosis. These histological alterations of hepatic tissues are due to the OS-induced LP that is evident from the elevated inflammatory markers and hepatic serum enzymes level in the current study followed by the exposure of AFB<sub>1</sub>. Our results are in line with a previous study, which reported that high concentration of ROS induced histopathological damages in the liver of rats (Abo-Hiemad *et al.*, 2022). However, GNK treatment remarkably ameliorated the histopathological damages induced after exposure to AFB<sub>1</sub>. These protective impacts of GNK are attributed to its potential free radical scavenging and anti-inflammatory activities.

**Conclusions:** AFB<sub>1</sub> administration potently elevated the levels of hepatic serum enzymes, inflammatory markers, and impaired histopathological profile in male albino rats. Besides, AFB<sub>1</sub> intoxication decreased the activities of antioxidant enzymes (CAT, SOD, GPx and GSR) and GSH content, thereby affecting the body's antioxidant defense capacity by increase in the concentration of ROS and the level of lipid peroxidation (MDA). Nonetheless, administration of GNK potentially alleviated the aforesaid AFB<sub>1</sub>-instigated damages in the dose-dependent manner owing to its ROS scavenging and anti-inflammatory potency.

**Authors contribution:** MUI and GZ designed the study. MUI and AI Performed the experiments. NE and MI performed statistical analysis. GZ supervised the study. MUI and GZ wrote the manuscript. All the authors read and approved the final version of the manuscript.

**Acknowledgements:** This work was supported by the Major Science and Technology Projects in Anhui Province (202003a06020009), the Key Laboratory of Biomedicine in Gene Diseases and Health of Anhui Higher Education Institutes, and Anhui Provincial Key Laboratory of the Conservation and Exploitation of Biological Resources.

## REFERENCES

- Abo-Hiemad HM, Nassar AY, Shatat AR, *et al.*, 2022. Protective effect of copper II-albumin complex against aflatoxin B<sub>1</sub>-induced hepatocellular toxicity: The impact of Nrf2, PPAR-γ and NF-κB in these protective effects. *J Food Biochem* e14160.
- Abrar M, Anjum FM, Butt MS, *et al.*, 2013. Aflatoxins: biosynthesis, occurrence, toxicity, and remedies. *Crit Rev Food Sci Nutr* 53:862-74.
- Aebi H, 1974. Catalase estimation. In *Methods of Enzymatic Analysis*. Academic press pp:673-84.
- Ali SS, Ahsan H, Zia MK, *et al.*, 2020. Understanding oxidants and antioxidants: Classical team with new players. *J Food Biochem* 44:13145.
- Ashraf A, Saleemi MK, Mohsin M, Gul ST, Zubair M, Muhammad F, Bhatti SA, Raza MR, Imran M, Irshad H, Zaheer I, Ahmed I, Raza A, Qureshi AS and Khan A, 2022. Pathological effects of graded doses of aflatoxin B<sub>1</sub> on the development of testes in juvenile white leghorn males. *Environmental Science and Pollution Research* <https://doi.org/10.1007/s11356-022-19324-6>.
- Bhatti SA, Khan MZ, Saleemi MK and Hassan ZU, 2021. Combating immunotoxicity of aflatoxin B<sub>1</sub> by dietary carbon supplementation in broiler chickens. *Environmental Science Pollution Research*, 35:49089-101. doi: 10.1007/s11356-021-14048-5
- Bao Y, Sun YW, Ji J, *et al.*, 2019. Genkwanin ameliorates adjuvant-induced arthritis in rats through inhibiting JAK/STAT and NF-κB signaling pathways. *Phytomedicine* 63:153036.

- Carlberg INCER and Mannervik BENGT, 1975. Purification and characterization of the flavoenzyme glutathione reductase from rat liver. *J Bio Chem* 250:5475-80.
- During A and Larondelle Y, 2013. The O-methylation of chrysin markedly improves its intestinal anti-inflammatory properties: structure-activity relationships of flavones. *Biochem Pharmacol* 86:1739-46.
- Faridha A, Faisal K and Akbarsha MA, 2006. Duration-dependent histopathological and histometric changes in the testis of aflatoxin B1-treated mice. *J Endocrinol Reprod* 10:117-33.
- Forman HJ and Zhang H, 2021. Targeting oxidative stress in disease: Promise and limitations of antioxidant therapy. *Nat Rev Drug Discov* 20:689-709.
- Gao Y, Liu F, Fang L, et al., 2014. Genkwanin inhibits proinflammatory mediators mainly through the regulation of miR-101/MKP-1/MAPK pathway in LPS-activated macrophages. *Plos one* 9:96741.
- Gell RM and Carbone I, 2019. HPLC quantitation of aflatoxin B1 from fungal mycelium culture. *J Microbiol Methods* 158:14-7.
- Haque MA, Wang Y, Shen Z, et al., 2020. Mycotoxin contamination and control strategy in human, domestic animal and poultry: A review. *Microb Pathog* 142:104095.
- Hayashi I, Morishita Y, Imai K, et al., 2007. High-throughput spectrophotometric assay of reactive oxygen species in serum. *Mutat Res Genet Toxicol Environ Mutagen* 631:55-61.
- Ijaz MU, Tahir A, Ahmed H, et al., 2022. Chemoprotective effect of vitexin against cisplatin-induced biochemical, spermatological, steroidogenic, hormonal, apoptotic and histopathological damages in the testes of Sprague-Dawley rats. *Saudi Pharm J* 30:519-26.
- Imran M, Cao S, Wan SF, Chen Z, Saleemi MK, Wang N, Naseem MN and Munawar J, 2020. Mycotoxins - a global one health concern: A review. *Agrobiological Records* 2: 1-16. <https://doi.org/10.47278/journal.abr/2020.008>
- Jiang Y, Hansen PJ, Xiao Y, et al., 2019. Aflatoxin compromises development of the preimplantation bovine embryo through mechanisms independent of reactive oxygen production. *J Dairy Sci* 102:10506-10513.
- Jollow DJ, Mitchell JR, Zampaglione NA, et al., 1974. Bromobenzene-induced liver necrosis. Protective role of glutathione and evidence for 3, 4-bromobenzene oxide as the hepatotoxic metabolite. *Pharmacology*, 11:151-69.
- Kakkar P, Das B and Viswanathan PN, 1984. A modified spectrophotometric assay of superoxide dismutase. *Indian J Biochem Biophys* 21:30-2.
- Kamdem LK, Meineke I, Gödtel-Armbrust U, et al., 2006. Dominant contribution of P450 3A4 to the hepatic carcinogenic activation of aflatoxin B1. *Chem Res Toxicol* 19:577-86.
- Knudsen AR, Andersen KJ, Hamilton-Dutoit, S, et al., 2016. Correlation between liver cell necrosis and circulating alanine aminotransferase after ischaemia/reperfusion injuries in the rat liver. *Int J Exp Pathol* 97:133-8.
- Li SH, Muhammad I, Yu HX, et al., 2019. Detection of Aflatoxin adducts as potential markers and the role of curcumin in alleviating AFB1-induced liver damage in chickens. *Ecotoxicol Environ Saf* 176:137-45.
- Marchese S, Polo A, Ariano A, et al., 2018. Aflatoxin B1 and M1: Biological Properties and Their Involvement in Cancer Development. *Toxins (Basel)* 10:214.
- Nagai K, Fukuno S, Oda A, et al., 2016. Protective effects of taurine on doxorubicin-induced acute hepatotoxicity through suppression of oxidative stress and apoptotic responses. *Anticancer drugs* 27:17-23.
- Nieskens TT, Peters JG, Dabaghie D, et al., 2018. Expression of organic anion transporter 1 or 3 in human kidney proximal tubule cells reduces cisplatin sensitivity. *Drug Metab Dispos* 46:592-9.
- Nonaka Y, Saito K, Hanioka N, et al., 2009. Determination of aflatoxins in food samples by automated on-line in-tube solid-phase microextraction coupled with liquid chromatography-mass spectrometry. *J Chromatogr A* 1216:4416-22.
- Ohkawa H, Ohishi N and Yagi K, 1979. Assay for lipid peroxidation in animal tissues by thiobarbituric acid reaction. *Anal Biochem* 95:351-8.
- Rakib A, Ahmed S, Islam MA, et al., 2020. Antipyretic and hepatoprotective potential of *Tinospora crispa* and investigation of possible lead compounds through in silico approaches. *Food Sci Nutr* 8:547-56.
- Rotruck JT, Pope AL, Ganther HE, et al., 1973. Selenium: biochemical role as a component of glutathione peroxidase. *Science* 179:588-90.
- Taniguchi K and Karin M, 2018. NF- $\kappa$ B, inflammation, immunity and cancer: coming of age. *Nat Rev Immunol* 18:309-24.
- Owumi SE, Irozuru CE, Arunsi UO, et al., 2022. Caffeic acid protects against DNA damage, oxidative and inflammatory mediated toxicities, and upregulated caspases activation in the hepatorenal system of rats treated with aflatoxin B1. *Toxicol* 207:1-12.
- Voth-Gaeddert LE, Stoker M, Torres O, et al., 2018. Association of aflatoxin exposure and height-for-age among young children in Guatemala. *Int J Environ Health Res* 28:280-92.